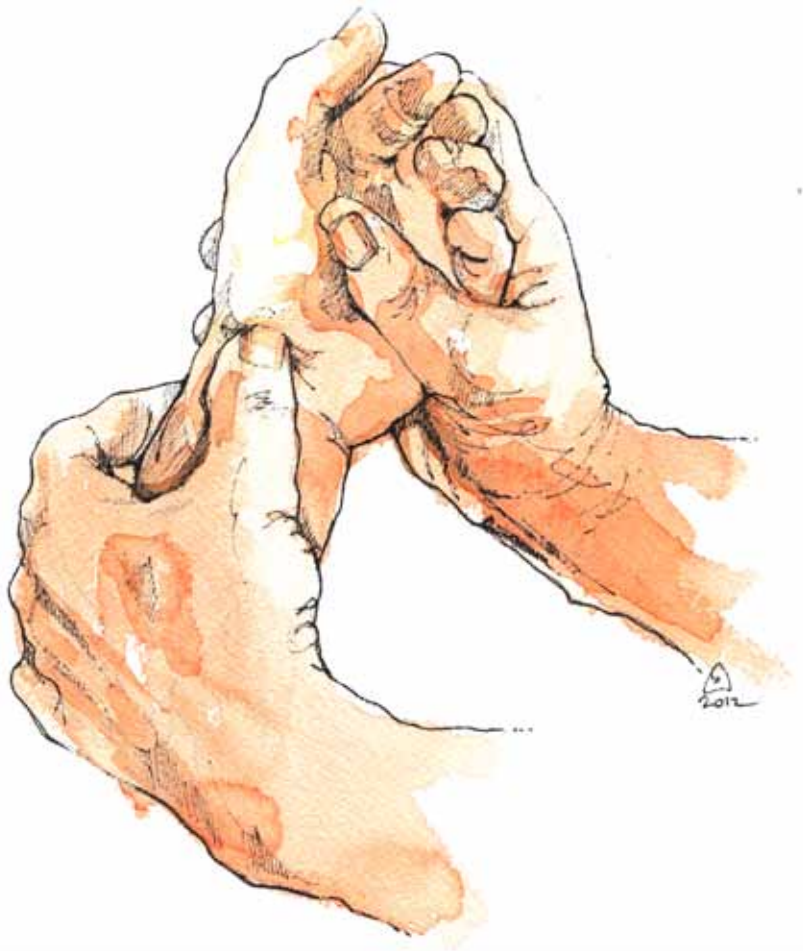



BSSH

The British Society for
Surgery of the Hand

Spring Scientific Meeting

3 - 4 MAY 2012

THE ROYAL COLLEGE
OF SURGEONS OF
ENGLAND



OFFICERS 2012

President

I A Trial

Immediate Past President

D A McGrouther

Vice President

S L Knight

Honorary Secretary

D J Shewring

Honorary Treasurer

R Savage

Editor in Chief

G E B Giddins

Council Members

SM Fullilove

I Grant

C Heras-Palou

M Hobson

S P Hodgson

B Jemec

R L Lester

I S H McNab

CONTENTS

OUTLINE PROGRAMME	2
THURSDAY 3 MAY	3
FRIDAY 4 MAY	9
POSTER PRESENTATIONS.....	21
BSSH AUDIT DATABASE	42
MEETING INFORMATION	43
REGISTRATION.....	43
VENUE.....	44
MISCELLANEOUS.....	45
CONTRIBUTORS INFORMATION.....	45
CONTINUING MEDICAL EDUCATION	45
SOCIETY DINNER.....	45
PRIZES	45
LECTURES	45
MEETINGS.....	45
MEDICAL AND TECHNICAL EXHIBITION	45
TRADE EXHIBITORS.....	46

OUTLINE PROGRAMME

THURSDAY 3 MAY

- 09:00 Registration and Refreshments
- 09:25 Welcome by the President
- 09:30 Sports Symposium, Part 1
- 11:00 Refreshments and Trade Exhibitions
- 11:30 Sports Symposium, Part 2
- 13:00 Luncheon and Trade Exhibitions
- 14:00 Guest Lecture
My experience in treating sportsmen in the USA, Dr M Baratz (Pittsburgh)
- 14:30 Free Paper Session
- 15:30 Refreshments and Trade Exhibitions
- 16:00 Free Paper Session
- 16:30 Guest Lecture
Commissioning in the hand, Professor J J Dias (Leicester)
- 17:00 Guest Lecture
Tackling mountains of adversity, Mr J Andrew
- 17:30 Business Meeting (open to Members and Associates only)
- 19:30 Society Dinner, The Royal College of Surgeons
for
- 20:00

FRIDAY 4 MAY

- 08:00 Registration
- 08:30 Surgical Dissection, Part 1
- 10:00 Refreshments and Trade Exhibitions
- 10:30 Surgical Dissection, Part 2
- 12:00 BSSH Audit Database
- 12:30 Luncheon and Trade Exhibitions
- 13:30 Guest Lecture
What is new in Kienböck's? Dr L de Smet (Leuven)
- 14:00 Free Paper Session
- 15:30 Refreshments and Trade Exhibitions
- 16:00 Free Paper Session
- 17:00 Close of Meeting

THURSDAY 3 MAY

09:00–14:00

09:00 Registration and Refreshments

09:25 Welcome by the President

SPORTS SYMPOSIUM, PART 1

Chairmen: Mr M J Hayton and Mr D J Shewring

09:30 The hand in sport – An overview
Mr M J Hayton (Wrightington)

09:45 Distal biceps rupture – The simple problem that's not
Dr M E Baratz (Pittsburgh)

10:00 Boutonniere – New functional Splint
Mr M J Hayton (Wrightington)

10:15 Scaphoid fracture – When can I play?
Mr R Eckersley (London)

10:30 “Pump Arm” – What, who and when
Mr C Heras-Palou (Derby)

10:45 TFCC injuries in athletes – Do they need treatment?
Mr T R Lindau (Derby)

11:00 Refreshments and Trade Exhibitions

SPORTS SYMPOSIUM, PART 2

Chairmen: Mr J L Hobby and Mr C A Pailthorpe

11:30 The Jersey finger – Fixation and return to play
Mr H P Giele (Oxford)

11:45 Thumb lig MPJ injuries – Why (wire) not
Mr D J Shewring (Cardiff)

12:00 “Buckle Hand” – Boxers CMCJ instability
Mr M J Hayton (Wrightington)

12:15 Radial styloid fractures – Rarely a benign injury
Mr D J Brown (Liverpool)

12:30 Delayed scapholunate ruptures in the athlete
Mr D A Campbell (Leeds)

12:45 Metacarpal fractures – Get me on the pitch doc
Mr D Warwick (Southampton)

13:00 Lunch and Trade Exhibitions

GUEST LECTURE

Chairman: Mr I A Trail

14:00 My experience treating sportsmen in the USA
Dr M E Baratz (Pittsburgh)

FREE PAPER SESSION

Chairmen: Mr C Heras-Palou and Miss B Jemec

14:30 Sibling recurrence risk in Dupuytren's disease

Mr T Bragg, Mr R Capstick, Mr H P Giele, Mr D Furniss (Oxford)

Background: Dupuytren's disease (DD) is a complex disease, with both genetic and environmental factors contributing to aetiology. We aimed to quantify the extent to which genetic factors predispose an individual to DD, through the calculation of sibling recurrence risk (λ_S), a standard measure of heritability risk. Furthermore, the influence of age and gender on λ_S was examined.

Methods: Five hundred and sixty-two index patients from the BSSH Genetics of Dupuytren's Disease (BSSH-GODD) database were contacted. One hundred and seventy-four had siblings who agreed to take part in the study. We randomly selected one hundred siblings, each from an independent index case, in order to reduce ascertainment bias. Each sibling was examined for DD - defined as the presence of a palmar nodule, cord or contracture - by a surgeon with over five years experience in diagnosing and treating DD. Controls were recruited from a non-diabetic ophthalmology outpatient clinic.

Results: There were no statistically significant differences in baseline characteristics, including diabetes mellitus, between the cases and controls. In siblings, 47% had DD, compared with 10.48% of controls ($p=1.006 \times 10^{-9}$), giving a λ_S of 4.48 (95% confidence interval 2.57–7.81). We found a higher λ_S for sisters of index patients compared to female controls, and also for siblings of younger index patients.

Conclusions: DD was significantly more common in the sibling group than in the control group. Our data accurately quantifies the magnitude of the genetic predisposition to DD. Further molecular studies are required to reveal the full genetic architecture of DD, which in turn may lead to new therapies.

14:35 Percutaneous needle fasciotomy for Dupuytren's disease: Eleven year follow-up

Mr I Roushdi, Mr C Hoare, Mr D Clark, Mr C Williams (Brighton)

Between December 1997 and March 2002, percutaneous needle fasciotomy was performed under local anaesthetic, and the cord was divided in the palm in one hundred and three digits.

There was one flexor tendon injury. One index, 11 middle, 41 little and 50 ring fingers were treated. The mean age of patients at the time of fasciotomy was sixty-seven (36 - 86).

Mean follow-up was eleven years. Mean pre-op MCP contracture was 42° and 5.7° post procedure. Mean pre-op PIP contracture was 17° and 15.8° post procedure.

We were able to follow up sixty-three digits. Eleven had died without further surgery and 32 digits were revised at a mean of 5 (1–11) years. Twenty digits were available for clinical review at 11 years. This group had a mean MCP contracture of 15° and PIP contracture of 19°. These had a milder pre-operative MCP contracture of 36° and PIP contracture of 8.5°, which corrected to 4° at the MCP and 8° at the PIP. The average recurrence rate in this subgroup was 1° per year per joint.

The group of patients who had been revised were significantly younger (mean age 63) ($p=0.03$) at the time of their fasciotomies, compared to those who had not had surgery (mean age 68) or those whose fasciotomies had outlived them (mean age 73). Needle fasciotomy is effective with acceptable long-term outcome, particularly in the older patient group with MCP disease.

14:40 Dupuytren's disease: Case study of six Singaporean patients of Chinese origin requiring surgical intervention

Dr R T J Yap, Mr A Chin, Professor A Tan (Singapore)

Introduction: Initial reports of Dupuytren's disease among European populations suggested Nordic ethnicity as the major cause (Early 1962, McFarlane 2002, and Reilly et al 2005). Diathesis of

Dupuytren's disease included age of onset, positive family history and other factors (Reilly et al 2005). Abe et al (2004) reported the disease among fifty-seven Japanese patients. Reports of incidence in other Asian populations are scarce.

Methodology: This report investigates the occurrence of Dupuytren's disease among the Singapore Chinese and aetiological causes of the disease, effects of stage at presentation on the effectiveness of surgical treatment of six Chinese patients in the Singapore General Hospital Department of Hand Surgery. Only those requiring surgical correction of the flexion contracture are reported.

Results: Patients with afflicted radial digits showed histological evidence consistent with that of Dupuytren's disease. All cases involving the little finger had poorer post-surgical outcome. Age, diabetes and alcohol predisposed the development of Dupuytren's disease and caused a higher grade of flexion contracture pre-operatively as well as poorer post-surgical outcome. Surgical intervention was advantageous and severe pre-operative afflictions may be better resolved with fasciectomy.

Conclusion: Patients' feedback suggested that Dupuytren's disease in Singaporean Chinese and other populations may only appear uncommon from lack of awareness, education and affluence.

14:45 Xiapex® in Dupuytren's disease - Early results, tips and wrinkles

Mr D Warwick, Mr D Graham (Southampton)

Introduction: Xiapex® has been recently introduced into the UK as an alternative to traditional treatment of Dupuytren's disease - either needle fasciotomy or surgical fasciectomy.

Materials and Methods: The author has injected forty-nine times with collagenase in 44 patients. The injection was given under ethyl chloride anaesthesia; the manipulation was given under lidocaine blockade.

Results: Complications were: three blood blisters, 2 axillary pain, 4 very painful swollen hands, 3 small skin splits. All these complications were transient and had fully recovered within a few days. There were three larger skin splits, all of which healed, the largest within 3 weeks with a full correction, following a 90° deformity in recurrent disease. Forty patients were highly satisfied.

Six patients had nuptorial cords affecting 2 digits treated simultaneously with one injection with full correction; 3 patients had 2 separate affected fingers treated by splitting the dose. 11/14 with a combined MP - PIP contracture had at least 50% correction of total extension deficit. All twenty-three patients with an MP contracture and all 3 isolated PIP contractures had a full correction. Two cords spontaneously ruptured without the need for formal manipulation. Split doses were latterly used to improve results.

Conclusion: Xiapex® is simple to use with a low temporary complication rate and very high patient and surgeon satisfaction.

14:55 Discussion

15:00 Trapezoid fractures - Perhaps not so rare

Mr N Kain, Mr C Heras-Palou (Derby)

Introduction: Trapezoid fractures are considered very rare with multiple single cases reported in the literature.

Aims: The aim of the study was to review all patients presenting to our unit with trapezoid fractures.

Methods: A retrospective case note review was conducted on all patients presenting with trapezoid fracture over the last ten years. Case notes were reviewed regarding mechanism of injury, fracture pattern, mode of diagnosis and time for diagnosis and treatment.

Results: Eleven patients were treated for trapezoid fractures over the ten-year period. Correct diagnosis was made in five cases on initial review. Most trapezoid fractures were diagnosed on CT scan. Fracture pattern was predominantly sagittal.

Conclusions: Fractures of the trapezoid should be suspected from the mechanism of injury, in particular axial force, and local tenderness. These fractures may be under diagnosed. Coronal fractures cannot be seen on plain standard radiographs. We recommend CT scan in case of clinical suspicion rather than basing a diagnosis on radiographs. Most of these fractures can be treated conservatively.

15:05 Outcome and return to work after distal radius fracture fixation

Mr N Johnson, Miss S Vinay, Miss K Mclean, Miss L Cutler (Leicester)

Aims: To review and compare outcome and return to work after distal radius fracture treated with volar locking plates or percutaneous k-wires.

Method: A retrospective comparative study of one hundred and twenty-seven patients with distal radius fractures was performed. Outcome was measured twelve months to 24 months post surgery using the PEM questionnaire and direct questioning regarding return to employment. Radiographs before and after fixation were reviewed. Forty patients were treated with k-wires and 87 with volar locking plates.

Results: No statistical difference was found between the two groups in PEM score and time to return to employment after surgery. Mean age of the volar plate group was fifty-seven (range 18 to 83) compared to 65 in the k-wire group (range 40 to 86). Twenty-two patients treated with volar plating were employed prior to injury and took an average of 61 days to return to work (range 3 to 196 days). Seventeen in the k-wire group were working and took an average of 77 days to return to work (range 28 to 168 days). Mean PEM score for the volar plating group was 43.8 compared to 44.5 for those who underwent k-wire fixation.

Conclusion: This study did not demonstrate that volar locking plates had superior outcome or enabled a patient to return to work quicker than treatment with k-wires at one to two years post-operatively.

15:10 Minimal access screw fixation of phalangeal fractures

Miss L Ovens, Mr G Bantick (London)

Phalangeal fracture fixation can be challenging and results can sometimes be poor. Open reduction internal fixation usually requires a long incision and wide exposure to reduce and fix the fracture. This results in tendon adhesions and scarring that limits movement of the finger. We present a new minimal access technique.

The fracture is manipulated and reduced under the image intensifier and bone reduction forceps applied directly onto the skin. If anatomical reduction is achieved, the minimal access procedure is used. A 1cm incision is made in the midlateral line over the fracture. Bone reduction forceps are applied, one point through the incision onto the centre of the bone fragment, the other through the skin on the other side. Internal fixation is now performed using one or two 1.5mm self-tapping screws. The lag screw technique is usually not necessary since the bone reduction forceps alone will maintain excellent compression of the fracture while screw fixation is performed.

The author has performed thirty cases. Functional outcome has been superior to cases where standard techniques have been used. There is less swelling and patients regain close to full range of movement. Operative time and recovery time is shorter. There have been no cases of bony non-union or delayed union. On two occasions it was not possible to complete the fixation with the minimal access technique.

Phalangeal fractures are a common injury and frequently require open reduction and internal fixation. This minimal access technique has wide potential application for these injuries.

15:15 **What fractures of the distal radius would we not fix?**
Mr M A C Craigen (Birmingham)

15:25 **Discussion**

15:30 **Refreshments and Trade Exhibitions**

FREE PAPER SESSION

Chairmen: Mr S P Hodgson and Mr G E B Giddins

16:00 **Analysis of explanted pyrolytic carbon prostheses**
Dr T Joyce, Mr M Bone, Mr G E B Giddins (Newcastle upon Tyne)

Introduction: Pyrolytic carbon prostheses are available for many of the small joints of the hand. While clinical results are mixed, to date no independent analysis of retrieved pyrolytic carbon prostheses has been reported. Many prostheses fail due to wear and therefore a study of articulating surfaces of explanted joints can indicate if they have worn during use in the body.

Methods and Materials: Ten explanted pyrolytic carbon components were obtained: four distal and two proximal components from proximal interphalangeal joints; one distal and one proximal from a metacarpophalangeal joint; and two components from carpometacarpal joints. All articulating surfaces were examined using a ZYGO non-contact profilometer (1nm resolution) to determine the roughness average (RA) of the surface and the presence of scratches, pitting and other damage. A total of 70 RA measurements were taken.

Results: ZYGO results showed that the majority of the articulating surfaces were unworn with near pristine surface finishes, even following use in vivo. Some surfaces showed signs of minor pitting and scratching.

Conclusion: The lack of damage on the articulating surfaces of the ten components suggests that they were unworn and therefore that the reason for removal was not wear related. Instead, clinical issues may have led to removal of these prostheses.

16:05 **Dorsal fracture subluxation of the proximal interphalangeal joint: A retrospective study of outcomes**
Mr P Loughenbury, Mr M Singh, Mr D Nikkhah, Mr J Rodrigues, Mr R Pinder, Mr W De Jager (Bradford)

Introduction: Dorsal fracture subluxation of the proximal interphalangeal joint (PIPJ) is a rare injury and reports of outcomes are limited to a number of small case series. Good results have been reported following treatment with open reduction internal fixation (ORIF), k-wire immobilisation and dynamic external fixation. We provide a review of outcomes in our unit using all three strategies.

Methods: Retrospective review of medical and physiotherapy notes over two years (August 2008 to August 2010). Timing of surgery, method of fixation, timing of metalwork removal, and post-operative physiotherapy attendance was recorded. Final range of movement (ROM) and fixed flexion deformity (FFD) were used as the main outcome measures.

Results: Eleven patients (9 male, 2 female) included: 4 dynamic external fixation, 3 immobilisation with k-wires, 3 ORIF and 1 elected for conservative treatment (excluded from results). Mean age was thirty-seven (17–58) years. All patients attended standard outpatient physiotherapy. Median follow-up was two months, time to surgery was 3 days (2–9) and time in external fixation 28 days (27–31). No complications were reported. Median final ROM was 85° (70–100°) for k-wire immobilisation, 70° (62–80°) for ORIF and 30° (27–38°) for dynamic external fixation. Median FFD was 0° for k-wire immobilisation, 15° (10–33°) for dynamic external fixation and 40° (28–50°) for ORIF.

Conclusion: Results were in line with those published in the literature. In our unit, immobilisation with k-wires appears to provide the best results. There is a scope for a randomised controlled trial to compare k-wire immobilisation, ORIF, and dynamic external fixation.

16:10 Medium term follow-up of proximal interphalangeal joint replacement (PIPJR)

Mr K Kunasingam, Mr F Wong, Mr C Williams (Brighton)

Aim: To review and assess subjectively patient satisfaction for medium term follow-up of un cemented pyrocarbon PIPJR in a cohort of osteoarthritic and rheumatoid patients from a south coast teaching hospital. To our knowledge no medium or long term results exist in current literature. Assessment was by postal survey using the patient evaluation measure (PEM) and the shortened disabilities of the arm, shoulder and hand (QuickDASH) questionnaires.

Methods: The patients were at least six months post surgery. No exclusions were made. A postal questionnaire with cover letter, PEM, QuickDASH and diagram sheet were sent out to the total cohort of eleven patients.

Results: Two patients were lost to follow-up. From a remaining cohort of nine patients, there were 11 joint replacements. All patients have returned the PEM and QuickDASH questionnaires, with tracing of the operated finger in maximum extension and flexion. The mean score was 21.7 for QuickDASH and 31.1% for PEM. The maximum extension and flexion achievable following PIPJ replacement were 0° and 83.1° respectively. The mean range of movement was 49.3° (Range 28.3–76.6°).

Conclusions: Interpretation of the mean results for both questionnaires show a good level of function and overall satisfaction after PIPJR. This supports our endorsement of the use of PIPJR as a treatment option for both osteoarthritic and rheumatoid PIPJs. A drawback of our study is not having pre-operative scores to contrast and then calculate statistical improvement pre-operatively and post-operatively.

16:15 When would I use a silastic, when would I use a two-part prosthesis at the PIP joint?

Mr M Bransby-Zachary (Glasgow)

16:25 Discussion

GUEST LECTURE

Chairman: Mr I A Trail

16:30 Commissioning in the Hand

Professor J J Dias (Leicester)

GUEST LECTURE

Chairman: Mr I A Trail

17:00 Tackling Mountains of Adversity

Mr J Andrew

17:30 Business Meeting

(Open to Members and Associates only.)

19:30 Society Dinner

The Royal College of Surgeons

FRIDAY 4 MAY

08:00–14:00

08:00 Registration

SURGICAL DISSECTION, PART 1

Chairmen: Mr I A Trail and Mr A C Watts

08:30 Elbow ligament and biceps reconstruction

Dr M E Baratz (Pittsburgh)

09:00 Ulna collateral ligament reconstruction at the thumb MCP

Mr M J Hayton (Wrightington)

09:30 Acute scapho-lunate repair

Mr D A Campbell (Leeds)

10:00 Refreshments and Trade Exhibitions

SURGICAL DISSECTION, PART 2

Chairmen: Mr I S H McNab and Mr A N M Fleming

10:30 Jersey finger

Mr S L Knight (Leeds)

11:00 Percutaneous scaphoid fixation

Mr C Heras-Palou (Derby)

11:30 Arthroscopic TFCC repair

Professor L de Smet (Leuven)

RESEARCH AND AUDIT

12:00 BSSH Audit Database

Miss S M Fullilove (Plymouth)

12:30 Lunch and Trade Exhibitions

GUEST LECTURE

Chairman: Mr I A Trail

13:30 What's new in Kienböck's?

Professor L de Smet (Leuven)

FREE PAPER SESSION

Chairmen: Mr R Murali and Mr S Talwalkar

14:00 A method of correcting the intrinsic minus (claw) hand via a single incision, palmar approach

Mr D Sammut (Windsor)

The interossei and lumbricals act to stabilise (and flex) the MP joints, while extending the IP joints, via their insertion into the extensor mechanism. Loss of this action secondary to paralysis produces the intrinsic minus (claw) hand, characterised by hyperextension of the MP joints and flexion of the IP joints. Without the opposing force of the intrinsics the vector of the long extensors causes the metacarpophalangeal joint to hyperextend. Coordinated flexion of the chain of digital joints is lost.

Numerous tendon transfer methods have been described to correct this imbalance; all have in common the restoration of a flexion force at the level of the MP joint, commonly by the lasso procedure described by Zancolli. This method relies on the long extensors also to produce exten-

sion of the IP joints as the lasso flexes the MP joints. It does not directly correct the reciprocal flexion of IP joints which can only be corrected if the tendon transfer is inserted into the extension mechanism. Traditionally this insertion has required a dual approach, one in the palm and one on the dorsum of each digit.

An original method of tendon transfer is presented, achieving insertion into the extensor mechanism (at the lumbrical tendon) via a single incision palmar approach. A brief review of the biomechanical principles and common methods is also presented.

14:05 Re-rupture rate following primary flexor tendon repair of the hand with potential contributing risk factors: Case series

Mr M Ibrahim, Dr M Rostom, Mr M Khan, Mr A Platt (Hull)

Introduction: Flexor tendon injuries of the hand are common with over three thousand one hundred and five per annum in the UK. We aimed to investigate re-rupture rate following primary flexor tendon repair at our institution and identify potential risk factors. This will help to improve this rate by careful consideration of risk factors.

Methods: We reviewed fifty-one consecutive patients with 101 flexor tendon injuries who underwent primary repair over a one-year period. Data was collected on age, gender, occupation, co morbidities, injured fingers, hand dominance, smoking status, zone of injury, time to surgery, surgeon grade, type of repair and suture and antibiotic use on included patients. Causes of re-rupture were examined.

Results and Statistics: Eleven out of 101 (10.9%) repaired tendons went on to re-rupture. Mean age was 35.8 for 38 males and 13 females. We compared primary tendon repairs that had a re-rupture to those that did not re-rupture. Univariate and multivariate analysis was undertaken to identify significant risk factors. A significantly higher tendon re-rupture rate was noted when the repair was performed on the dominant hand ($p=0.009$), in Zone 2 ($p=0.001$), and when a delay of more than 72 hours occurred ($p=0.01$). Multivariate regression analysis identified repair in Zone 2 injuries to be the most significant predictor of re-rupture.

Conclusions: Our rate of re-rupture is 10.9%. This is within the higher published figures. This was associated with delay in surgery, repair on dominant hand and Zone 2 repairs. Careful consideration of these factors, especially Zone 2 injuries, is crucial to reduce this rate.

14:10 A systematic review of the rehabilitation regimens following extensor tendon injuries of the hand

Mr C Y Ng, Miss J Chalmer, Mr D Macdonald, Mr S Mehta, Dr D Nuttall, Mr A Watts (Wigan)

Introduction: There is no consensus on the most effective rehabilitation regimen following extensor tendon injuries of the hand. This systematic review evaluates the reported outcomes of the various regimens.

Methods: The Cochrane, MEDLINE, EMBASE, CINAHL, AMED, PEDro, OTseeker databases were searched for any prospective randomised clinical trials which compared different rehabilitation regimens for acute extensor tendon injuries in adults.

Results: Five papers met the inclusion criteria. The regimens studied could be broadly divided into static immobilisation, dynamic splinting and early active motion (EAM). There was no standard format of reporting. The sample size ranged from thirty-four to 100 patients. The duration of follow-up ranged from eight to 24 weeks. Overall, patients' total active motion (TAM) improved with time. At six weeks, patients treated using dynamic splinting regained greater TAM than those treated with static immobilisation. The difference appeared to diminish beyond twelve weeks. There was no statistically significant difference in the proportion of good or excellent results between dynamic splinting and EAM. Only three cases of tendon re-ruptures were reported in one study.

Conclusion: Following extensor tendon repair, early mobilisation regimens (active and passive) achieve quicker recovery of motion than static immobilisation but the long-term outcome appears to be similar. Incidence of tendon re-rupture is low. Given the comparable outcomes between dynamic splinting and EAM, we therefore favour EAM which is simpler and more convenient.

14:15 Discussion

14:20 What is optimum for a flexor tendon repair?

Mr J S Watson (Manchester)

14:30 Audit of a freehand technique of ulnar shortening osteotomy

Mr P Magill, Ms C Fox, Mr J O'Beirne (Waterford)

Introduction: Extra-articular ulnar shortening osteotomy has been shown to be effective in relieving the symptoms of ulnar impingement. Freehand techniques are often criticised for high rates of non-union due to difficulty in achieving parallel cuts. Therefore, many devices exist to improve cut symmetry. The practice in our unit is a freehand technique, which has been customised by the senior surgeon (JO'B). We aimed to audit our non-union rate for this procedure.

Methods: A radiographic and chart review was completed on all the cases performed by the senior surgeon. A photographic description of the operative technique is presented.

Results: Twenty osteotomies in 19 patients were performed. Standard post-operative follow-up was six weeks, three months and then discharge from service at six months if symptoms had resolved with both clinical and radiographic evidence of union at the osteotomy site. Eighteen of the 20 osteotomies completed the standard follow-up protocol. Two of these patients subsequently requested removal of the plate due to tenderness. Non-union occurred in two cases. One patient developed an infected non-union and was later diagnosed with an underlying immunological deficiency. The second patient developed atrophic non-union and was revised at ten months with the same technique. Revision surgery was successful in achieving union in the standard time frame.

Conclusion: The technique described achieves a high rate of union without the requirement for any custom surgical devices.

14:35 Four corner fusion with the spider plate - The Wrightington experience

Mr R Sreekumar, Ms A Birch, Mr M J Hayton, Mr I A Trail (Wigan)

Introduction: Four corner fusion as a procedure was advocated for SLAC and SNAC wrists in the 1980's. The earlier methods of fixation were with K-wires, screws and staples. In 1999, the spider plate was introduced. Review of the literature has shown variable outcomes.

Materials and Methods: We reviewed all the four corner fusions done in our institution from 2005 to 2010. In this period fifty-seven wrists were operated on in 56 patients. We identified thirty-nine patients who had undergone spider plate fixation. We reviewed twenty-six of these patients in clinic with clinical examination, X-rays and questionnaire.

Results: Of the thirty-nine patients, there were fifteen SLAC wrists and 24 SNAC wrists. The average follow-up was fifty-seven months. Twelve patients reported pain, with a median score of 4 on the VAS. Grip on the operated side was 69% of the normal side. Range of movements were 40% of normal limb for combined flexion-extension and 33% for ulnar-radial deviation. Patient rated wrist experience was 31.86 for pain and 29.462 for function. Twenty-four of the 26 patients reviewed achieved union. There were three implant removals for impingement pain. Two patients were converted to wrist fusion.

Discussion: We have used the spider plate since 2005 and this review at an average of fifty-seven months confirms good union rates. However, the outcomes are very variable and appear related to the functional activity.

14:40 Is it possible to quantify dart throwing motion of the wrist in normal volunteers?

Mr H P Singh, Dr M Brinkhorst, Dr H Salijper, Professor S Hovius, Professor J J Dias (Leicester)

Most routine activities in daily life involve coupled motions at the wrist with variable combinations of radio-ulnar deviation and flexion-extension rather than a single plane of motion. Dart throwing is a coupled motion that moves through an arc from radial deviation and extension to ulnar deviation and flexion. But quantification of this movement has been difficult and requires complex cross-sectional radiological technique.

Ten healthy volunteers were assessed with flexible biaxial electrogoniometry in standard position of wrist for kinematic assessment of movement to quantify the coupled effect in the dart thrower's motion. Full range of flexion-extension, ulnar-radial deviation, dart throwing and circumduction was measured by analysing the digital output producing a visual display of the results as Lissajous' figures. This allowed mathematical measurement of total arc of motion in dart thrower's plane and comparison with flexion extension and ulnar-radial deviation plane.

The mean arc of motion in the dart throwing plane was 102° (range 58 to 135°). This is three-fourths of the maximum arc of motion in the flexion extension plane (mean of 142°) (range 110–172°). The arc of motion in the dart throwing plane is nearly double the range in the ulnar-radial deviation plane (mean 68° range 54 to 86°). The dart throwing plane axis lies at a mean angle of 14° anticlockwise to the flexion extension plane for right hand and clockwise for the left hand.

The use of this technique can be extended to measurement of changes in the dart throwing plane in diseased hands.

14:45 Does the insertion of a pyrocarbon spacer improve a patient's outcome after trapeziectomy? - A study by subjective assessment

Mr V Rajamani, Mr R Walker (Abergavenny)

Background: Trapeziectomy for first carpometacarpal joint arthritis is a standard procedure with good outcome, but this technique carries the risk of shortening of the thumb ray. Trapeziectomy with interposition of a pyrocarbon spacer may be a worthwhile alternative technique. We compared the outcome of trapeziectomy alone with trapeziectomy and insertion of a pyrocarbon spacer.

Methods: Between 2006 and 2010, seventy-two patients underwent trapeziectomy surgery (by a single surgeon). Forty-five patients underwent trapeziectomy alone (Group 1). Of the remaining twenty-seven patients, 14 (Group 2) had a pyrocarbon spacer inserted post-trapeziectomy. In the other thirteen patients the trial spacer was unstable and hence not inserted. The outcome was assessed with a subjective questionnaire rated for pain, strength and stiffness. Subjective assessment of grip strengths with certain daily activities was done. The pre-operative score was calculated retrospectively based on the patient's memory.

Results: The mean age of the patients was sixty-four. Of these, fifty-five were female. The mean follow-up period was thirty-seven months for Group 1 and 11 months for Group 2 (6-21months). Two patients in Group 1 had re-operation with tendon insertion. One patient in Group 2 had removal of the spacer. Eighty-five percent in both groups had a good to excellent outcome score. Although there was no statistical significance, there was a trend (in Box and whisker plot) towards increased subjective pincer and key grip strength in Group 2.

Conclusion: The short term outcome of pyrocarbon spacer insertion compared to trapeziectomy alone group was similar but with a possible increase in key and pincer grip strength.

14:50 Fascia lata sling ligament reconstruction for Z-deformity and adduction contracture following interposition arthroplasty of first carpometacarpal joint

Mr A Mishra, Miss N Alam, Mr A Iqbal (Liverpool)

Introduction: Management of deformity of the base of the thumb following surgical correction of first carpometacarpal joint arthritis is difficult.

Patient and Methods: We present a lady who developed adduction and Z-deformity of the thumb following trapeziectomy and FCR ligament reconstruction and tendon interposition. Fascia lata was used for correction of Z-deformity and adduction contracture of the first carpometacarpal joint by creating a check-rein ligament, using a fascia lata sling passed through a drill hole in the base of the first metacarpal, and looped around insertion of ECRL and finally sutured to itself on the radial side of the first metacarpal. The hyperextension of the MCPJ was also corrected simultaneously with a small strip of fascia lata across remnant of attenuated volar plate and a blocking K-wire was used to splint the thumb in adduction.

Results: The patient regained her use of the hand and correction of deformity. She was very pleased with the result and is now awaiting similar surgery on the other side.

Conclusion: Fascia lata for re-do CMCJ ligament reconstruction proved to be a useful technique and may have a wider application.

14:55 Discussion

15:00 An unusual presentation of bicipital osteochondroma causing painful clicking around the wrist

Mr A Alsaadi, Mr J Stanton, Mr M Abass (Colchester)

Introduction: Osteochondromas of bicipital tuberosity are rare. They are commonly metaphyseal benign tumours of long bones. Very few cases of bicipital tuberosity's osteochondroma are reported in the literature. The usual presenting symptoms were pain and reduced rotation of the elbow. The common feature in all these cases was prominent bicipital tuberosity. However, none of these cases described a painful clunk in the wrist as a presenting complaint.

Method: We present a young lady with several years history of a painful clunk in her wrist. Her case presents a diagnostic challenge as the pain and the click are originated from her elbow and radiated down her forearm to the wrist. An MRI scan of her wrist was arranged which appeared normal. Her elbow radiographs showed a significantly enlarged bicipital tuberosity. Attention was then focused more proximally in the forearm. Further radiological studies and examination under anaesthesia of her elbow confirmed the prominent bicipital tuberosity clicking when the forearm was moved from supination to pronation. The definitive open procedure was performed and her symptoms improved after surgical excision of the osteochondroma. The histopathological examination of the lesion confirmed the osteochondroma and she remained asymptomatic at six months follow-up.

Conclusion: The diagnosis of a painful clunk in the wrist due to elbow pathology could be challenging. An enlarged radial tuberosity on a plain radiograph should raise a high index of suspicion. The MRI scans and the examination under image intensification are useful means of diagnosis.

15:05 Emergency cross-over limb replantation after bilateral traumatic amputation

Mr W Holmes, Mr A Williams, Ms K Everitt, Professor S P J Kay, Ms G Bourke (Leeds)

We present a case of a cross-over limb replantation following traumatic bilateral arm amputation due to a train injury.

With ipsilateral replantation not possible, our patient underwent replant of the left forearm onto the right side at the level of the proximal forearm. Follow-up at two years reveals a sensate hand, with good recovery of her long flexors of the hand and extensors to the wrist. Functional outcome

was measured using the DASH questionnaire, Moberg seven object pick up test and Chen's criteria. We demonstrate a high level of function compared to the contralateral prosthetic limb.

There have only been six similar cases ever described in the international literature. We review these and make a critical comparison of outcome. Although a rare circumstance, a cross arm transplant can provide a level of function that is far superior to a prosthesis and allow an element of independent living that would otherwise be impossible with bilateral prostheses. Cross-arm transfer should be considered for bilateral arm amputations where direct coaptation and limb salvage are not possible.

15:10 A comparison of PEM and quickDASH scores in day case hand surgery: Pre-operatively, six weeks post-operatively and one year post-operatively

Mr A Procter, Mr T Halsey, Mr M Wijeratna, Mr P Johnston (Cambridge)

Introduction and Aims: Patient Reported Outcome Measures (PROMs) are becoming used increasingly, both in research reporting and in clinical practice. The Department of Health is currently investigating ways of incorporating PROMs to measure individuals' and departments' clinical efficacy. This study aims to compare the Patient Evaluation Measure (PEM) and quickDASH (shortened version of Disability of Arm, Shoulder and Hand) in evaluating outcomes following day case hand surgery.

Materials and Methods: Patients completed PEM and quickDASH scores pre-operatively (n=219) and six weeks (n=162) and one year (n=74) post-operatively as part of routine clinical audit. This cohort has already been reported at the earlier post-operative time point at the BSSH meeting, Autumn 2010.

Results and Statistics: Spearman's rank correlation coefficient (rs) for PEM vs. quickDASH were: pre-operative rs=0.783 (p<0.01), six week post-operative rs=0.813 (p<0.01), one year post-operative rs=0.749 (p<0.01). As expected, median PEM & quickDASH scores fell significantly post-operatively (paired Wilcoxon test); but there was not a significant further fall comparing scores at six weeks and over one year (PEM p=0.196; quickDASH p=0.955). The 'pre-operative - post-operative' effect sizes were calculated (PEM=0.88, quickDASH=0.74).

Conclusions and Clinical Reference: Our results support that PEM is more responsive to change in this clinical context than quickDASH. As the two scores are highly correlated, there appears no need to employ both. As there is no evidence for a change in score from the six week to the one year post-operative time point, this earlier point can confidently be used for auditing clinical outcomes, reducing need for longer term follow-up (unless clinically indicated).

15:15 The atasoy flap: Patient vs surgeon perception of outcome

Mr A Sadri, Mr M Chowdhry, Mr J Patel, Mr J May, Mr G Moir (London)

Introduction: Atasoy or V-Y volar advancement flap has become a popular surgical option for transverse and dorsal oblique finger tip amputations. Although several series have reported their experience with the Atasoy flap aesthetic and functional outcome has been from the surgeons perspective only. We compared patient with surgeon reported outcomes to see if patients in reality consider this a worthwhile procedure.

Methods: Patients who had undergone Atasoy flap fingertip reconstruction were evaluated with the following validated assessment tools: Disabilities of the Arm, Shoulder and Hand (DASH) Questionnaire, Dermatology Life Quality Index (DLQI), Derriford Appearance Scale (DAS-24), and Manchester Scar Scale (MSS). Finally our own aesthetic outcome questionnaire was given to patients and three senior surgeons.

Results: Thirty-two patients with Atasoy flap reconstruction were evaluated. According to the validated assessment tools (DASH, DAS-24, DLQI), the Atasoy flap seems to have a negative impact on the patients' perceived psychological and functional impairment following surgery. Our own

assessment tool revealed that there was a discrepancy regarding aesthetic outcome reported from patients and surgeons, with surgeons scoring aesthetic outcome higher than patients.

Conclusion: This is the first study to investigate patient reported functional and aesthetic outcomes following finger tip reconstruction with the Atasoy flap. Our results show that although surgeons believe that this is a reasonable reconstructive option there is considerable associated morbidity. Pre-operative counselling on long-term outcome will likely lead to improved satisfaction as patient expectations are better managed.

15:20 Reconstruction of chronic distal biceps ruptures with Achilles tendon allograft

Mr J C Talbot, Dr T Carter, Professor L Funk, Mr A Watts (Wrightington)

Introduction: Chronic distal biceps tendon tears are uncommon and patients present with weakness, poor cosmetic appearance and biceps cramping. Late direct repair is not usually possible due to proximal tendon retraction, and interposition grafting may be required. We use an Achilles tendon allograft to avoid donor site morbidity.

Materials: Eight consecutive patients with symptomatic chronic distal biceps tears underwent reconstruction at an average twenty-two months post-rupture. Patients were reviewed post-operatively using a telephone interview which included Oxford Elbow score, subjective satisfaction, pain and strength scores and specifically patients were asked about biceps muscle cramp.

Results: All patients were male, with a mean age of forty-five years (range 29–64), with surgery performed exclusively in the dominant arm. Mean follow-up was twenty months (range 3–33). Five underwent distal fixation with suture anchors and 3 using an Endobutton technique. There were no peri-operative complications, but two late failures were seen in the suture anchor group (both following further trauma).

Seven patients reported pre-operative biceps cramping, compared to only two post-surgery (both in the failed group). Median post-operative Oxford Elbow score was 42 (inter-quartile range 35–45) and mean satisfaction was 60% improvement (80% excluding failures). No patient reported any loss of elbow/forearm movement. Median post-operative pain was 1/10 (IQR 0–5) and strength was comparable to the contralateral side in 6/8 patients.

Conclusion: Achilles allograft reconstruction of chronic distal biceps ruptures results in good patient outcome scores and significantly reduced cramping of the affected biceps muscle when successful tendon re-attachment is achieved.

15:25 Discussion

15:30 Refreshments and Trade Exhibitions

FREE PAPER SESSION

Chairmen: Mr R Savage and Mr J S Watson

16:00 The impact of a multidisciplinary hand centre on the hand trauma service in a plastic surgery unit

Dr K Sharma, Miss P Witt, Mr T Nanidis, Dr E Karagergou, Mr R Caulfield, Miss R Harper (Sheffield)

Introduction: The Sheffield hand centre was established with the aim of running a streamlined hand trauma service employing a multidisciplinary approach. The aim of this evaluation is to assess the hand trauma service before and after the establishment of the hand centre and to evaluate its impact on the quality of service provision.

Methods: Data was collected prospectively over a one-month period, October 2009 and September 2011, on a random sample of ninety-three and 96 patients respectively. The following criteria were evaluated and compared: waiting times from referral to initial assessment, use of general

emergency theatres versus dedicated plastic surgery trauma lists, grade of the most senior surgeon present in theatre and type of anaesthetic intervention.

Results: Time from referral to assessment was on average 2.6 hours in 2009 and 2.27 hours in 2011. The use of the emergency theatres decreased by 43% in 2009 (53%) compared to 2011 (10%). Consultants were present in 50% of cases in 2011 compared to 26% in 2009. There has been a 14% increase in the use of regional anaesthesia in 2009 versus 2011.

Conclusion: The establishment of a hand centre has increased the standard of our services. There is lesser out of hours operating and a more consultant led service compliant with CEPOD guidelines. Utilisation of theatre time has become more effective due to changes in anaesthetic practice and higher patient throughput. Moreover there is an increase in training opportunities for junior doctors under direct consultant supervision.

16:05 Avulsion type exostosis of the hand: Exostosis variant or atypical osteochondroma?
Mr C Wearn, Mr H Bella, Mrs A Jester (Birmingham)

Avulsion type exostoses have been described in the lower limb and pelvis but no cases occurring in the hand have been reported in the literature. An exostosis may be defined as any abnormal benign outgrowth from the surface of a bone, however in the literature it has been used synonymously with the term osteochondroma. A true osteochondroma is a benign osteo-cartilaginous tumour constituting 20–50% of all benign bone tumours and may be solitary or associated with the autosomal dominant inherited condition Hereditary Multiple Exostosis (HME). Exostosis variants that resemble an osteochondroma may occur after traumatic injury and various types have been described in the hand. These rare lesions include Subungual exostosis, Turret exostosis, Benign parosteal osteochondromatous proliferation (BPOP or Nora's lesion) and Florid reactive periostitis.

The authors report the case of an avulsion type post-traumatic exostosis of the proximal phalanx in a child requiring surgical excision due to symptoms and proximal interphalangeal joint (PIPJ) deformity. The lesion was radiologically and histologically distinct from an osteochondroma, however, it could not be categorised into the aforementioned types of exostosis variant. We postulate that a closed avulsion injury to a collateral ligament of the PIPJ resulted in a sub-periosteal haematoma, later ossifying in response to osteogenic signals from the periosteum and the avulsed bone fragment within the haematoma.

This case illustrates the wide differential diagnosis for post-traumatic exostoses occurring in the hand. Most are benign conditions that can be diagnosed radiologically and may require excision if symptomatic, causing deformity or impairing function.

16:10 Macroductyly - Options and outcomes
Miss H Richards, Mr J Hardwicke, Miss R Lester (Birmingham)

Introduction: Macroductyly is a rare congenital disorder of overgrowth affecting digits of the upper or lower limb. We report outcomes of thirty-six patients diagnosed with macroductyly. The goals of surgery are to control or reduce size, whilst maintaining sensibility and function.

Method: Patient outcomes were measured, using a postal questionnaire with the upper limb assessed using the Disability - Arm, Shoulder, Hand (DASH) score and the Birmingham Children's Hospital Hand and Upper Limb Service Reach Out questionnaire. For the lower limb, the Paediatric Outcomes Data Collection Instrument (PODCI; Pediatric Orthopedic Society of North America, Rosemont, USA), was used.

Results: Average age at presentation was forty-six months and there was an equal sex distribution. 82% were managed surgically and the remainder were managed conservatively. All of those managed conservatively had a static form of the disease whereas all those with the progressive form were treated surgically. We had a 50% response rate and found no significant difference in outcome (functional, cosmetic, psychosocial) between those managed surgically or conservatively.

We believe this reflects the fact that surgery was only carried out in those with severe or progressive disease and conservative management was reserved for those who were less severely affected.

Conclusion: Macrodactyly remains a complex problem and plastic surgeons need to be aware of a large range of management options available for use. The need for repeated procedures must be recognised particularly in progressive cases. In the vast majority of cases the functional and cosmetic outcome are good, with good patient acceptance.

16:15 Follow-up following carpal tunnel decompression: Two weeks or two months?

Miss A Tam, Mr O Tillo, Mr J Haeney, Mr M Riaz (Hull)

Introduction: Follow-up after carpal tunnel decompression (CTD) varies widely between and within units. The aim of this study was to standardise the review of patients following CTD in a cost effective and safe regime.

Methods: A retrospective case note review of one hundred and two patients who underwent unilateral carpal tunnel decompression was conducted. Outcomes, complications, planned follow-up and actual outpatient attendance was reviewed. Cost comparison analysis was performed between two common follow-up regimes.

Results: Ninety-eight patients were included. Two groups were identified depending on the planned first review: early (2 weeks, 51 patients) and late (6–8 weeks, 47 patients). No significant difference was found between the groups in age, comorbidities, surgical techniques and rate of complications. The number of outpatient visits was significantly higher in the early review group (Table 1). This increase was highly significant in patients without complications ($p < 0.001$). Most minor complications ($n=18$) resolved within two months post-operatively. All major complications ($n=4$) self-referred to the ward or clinic rather than being identified at planned follow-up. Adopting the late follow-up regime reduces outpatient visits by 27%. This results in an annual saving of £6,762 on CTD performed in our department.

Conclusion: A late follow-up regime for CTD is safe and cost effective in well informed patients.

HC visits per patient	Number and percentage of patients	
	2-weeks group	8-weeks group
1	18 (35%)	34 (72%)
2	27 (53%)	11 (23%)
3	4 (8%)	2 (5%)
4	2 (4%)	0 (0%)
Total patients	51 (100%)	47 (100%)
Total Visits	92	62
Average visit per patient	1.8	1.32

Table 1: Pattern of patient visits to hand clinic (HC) in the two groups of follow-up.

16:20 The role of joint denervation in the treatment of basal thumb osteoarthritis

Mr N Kain, Mrs M Arundell, Mrs M Bradley, Mr C Heras-Palou, Professor F D Burke (Derby)

Introduction: Joint denervation is an effective surgical option for treating basal thumb OA. This has the advantage of maintaining bony anatomy and stability whilst improving pain symptoms. Although trapeziectomy is the gold standard, more radical surgery is required with reduction in stability/grip strength.

Aims: To assess the effectiveness of joint denervation compared to trapeziectomy for treatment of first CMC joint osteoarthritis. To establish the role of joint denervation in the patient care pathway for the treatment of basal thumb OA.

Methods: A prospective study was conducted over four years. Participation was offered to patients where surgery was clinically indicated for 1st CMCJ OA. Simple thumb movements, isometric static and isotonic dynamic functions of the thumb were measured with respective VAS scores at baseline, six months and 12 months post-op.

Results: Forty-seven patients were included in the study - 11 primary trapeziectomy, 36 denervation. At one year, all movements and functions of the thumb in the denervation group improved (P NS). In the trapeziectomy group, VAS scores post assessment of simple thumb movements and pinch strength improved ($p < 0.05$), with no significant change in function. At three years post denervation, 9 patients (33%) had undergone secondary trapeziectomy.

Conclusion: Although denervation improved the movements and function of the thumb at one year, it was less effective in treating pain compared to trapeziectomy. At three years, one third of denervation patients required trapeziectomy as a secondary procedure. We suggest denervation is a reasonable option to offer patients prior to consideration of trapeziectomy.

References:

Cozzi EP. Dénervation des articulations du poignet et de la main. In: Tubiana R ed. *Traité de Chirurgie de la Main*. Tome IV. Paris: Masson; 1991: 781–787.

16:25 Discussion

16:35 Education and guidelines can initiate delivery of early, rationalised antibiotic therapy in hand infections

Dr J Dunne, Mr R Pinder, Dr H Bennett, Dr A Sohal, Mr S Majumder (Wakefield)

Introduction: Hand infections are common and represent approximately 20% of hand surgery admissions. Without prompt antibiotic treatment they can rapidly progress and have disastrous effects on hand function.

Methods: An initial study was carried out including all admissions with hand infections deemed to require intravenous (IV) antibiotics, to our plastic surgery unit over one month. Areas of delay were time from first doctor assessment to: (1) insertion of peripheral venous cannula, and (2) first dose of antibiotics. Antibiotic guidelines were produced and published locally, and staff were educated in both the plastic surgery and emergency departments. A further study analysed the effects of these interventions.

Results: A total of forty-five patients were included in the studies - 22 in the first study (2009), and 23 in the repeat (2011). The key findings showed improvements in the time from first doctor assessment to first antibiotic dose (mean 281 minutes [95% CI:214 to 348] vs. 121 minutes [95% CI:78 to 165; $P < 0.001$] respectively) and time from plastic surgery assessment to first dose of IV antibiotics (mean 226 minutes [95% CI:142 to 309] vs. 101 minutes [95% CI:58 to 145; $P = 0.02$] respectively).

Conclusions: Encouraging, oral antibiotic prescription in referring hospitals leads to earlier administration, as IV antibiotics may be delayed due to transfer. The introduction of a simple antibiotic protocol with guidelines specifying the need for IV or oral administration, and education of both triage and surgical staff, are effective tools which can significantly improve treatment in hand infections.

16:40 'Beware of the dog' sign is just not enough

Mr Z Shariff, Dr J Jaroszkiewicz, Miss S Jivan (Wakefield)

More than five thousand postal workers suffer dog bites each year. Most sustain bites to their hands.

Method: We conducted a retrospective audit of all dog bites seen and treated at Pinderfields Hospital, Wakefield, between April 2010 and March 2011. Data was collected using hospital databases.

Analysis included patient demographics; place and nature of incident; type of dog; treatment and wound cultures.

Results: Sixty-seven hand related dog bites were treated over the twelve-month period. Eleven patients sustained their injuries whilst trying to post items through front door letter boxes. Of the eleven patients, 2 needed nail bed repair, 1 flexor sheath washout, 7 toilet only and 1 refused admission.

Conclusion: Even ‘minor’ injuries have major resource and financial implications. Time off work, sick pay, hospital costs which include theatre, dressings and hand therapy all need to be taken into consideration. Letterbox related bites are wholly preventable. The 1991 Dangerous Dogs Act states that a dog owner can be prosecuted if the animal bites someone in a public place. We feel that dog owners should also be liable if people are bitten through the letter box. Just as dogs should be muzzled in public places, it should be compulsory for all dog owners to have letter cages/post guards which hang behind the letter box on the door to collect the post and stop the dog chewing on both the letters and the hand of the person posting the item! A ‘Beware of the Dog’ sign is just not enough.

16:45 Dog bite injuries to the hand

Mr Z Shariff, Dr J Jaroszkiewicz, Miss S Jivan (Wakefield)

Background: Each year in the UK, approximately 250,000 people sustain dog bite injuries. A minority of these need surgical intervention, mostly for hand and upper limb injuries. Our aim was to assess the outcomes of dog bite related hand injuries seen and treated in our plastic surgery department at Pinderfields Hospital, Wakefield.

Method: We conducted a retrospective audit for the period between April 2010 and March 2011. We analysed the following data: patient demographics, place and nature of the incident, breed of dog, type of injury, treatment and wound cultures.

Results: We treated ninety-six patients with dog bites between April 2010 and March 2011. Of these, sixty-seven sustained hand injuries. All but one required wound debridement and exploration, however, one patient refused surgery. The male to female ratio of operated patients was 41:24. Three patients required digital nerve repair, 2 flexor sheath washouts, 1 volar plate repair, 2 nail bed repairs and 1 terminalization of the finger. Separating two fighting dogs was the commonest cause of dog bites. Eleven patients sustained their injuries whilst trying to post items through front door letter boxes.

Conclusion: On average at least one dog bite injury of the hand is treated in our department per week. Educating dog owners of the dangers of trying to separate fighting dogs and encouraging use of muzzles would prevent such admissions. This in turn will reduce the resource and cost burden on an already stretched service.

16:50 Do adjuncts to standard consenting procedure improve comprehension and recall? A randomised controlled trial of patient recall of risks in day case hand surgery

Mr Z Khan, Dr A Sayers, Mr M Khattak, Mr N Eastley, Mr S Naima (Dudley)

Introduction: Informed consent implies that the person undergoing an intervention thoroughly understands its pros and cons. We conducted a randomised controlled trial to evaluate patients recall of complications associated with day case hand surgery and the effects of age and socio-economic factors. Patients’ wishes on the extent and type of information provided were also evaluated.

Methodology: All patients undergoing elective day case hand surgery from August 2009 to February 2010 were recruited into this trial. Patients were randomised into two groups, one receiving verbal information and the second group both verbal and written information, detailing the complications associated with surgery. On their first post-op visit, a test of recall of complications was conducted along with information on patient preferences.

Results: A variety of one hundred and twenty-four cases were recruited. Forty-eight were included in group 1 (verbal only) and 66 in group 2 (verbal & written information). No statistically significant ($P=0.1$) difference was noted in the recall between the two groups. No effect of gender, age or socioeconomic status was noted. More patients preferred both written and verbal information. Preference for knowledge of rates of complications was higher if risk was 1 in 100 or more.

Conclusion: Informed consenting is a contentious issue. We focussed on recall rather than comprehension. Our results don't show any significant difference in patient recall depending on the type of consenting method. Furthermore, no effect of gender or socioeconomic status was noted. Nevertheless, we still propose that patients should receive as much information as possible before undergoing any intervention.

16:55 Discussion

17:00 Close of meeting

1 The cutaneous ligaments of the finger: Cleland and Grayson

Dr R Zwanenburg, Professor P Werker, Professor D A McGrouther (Groningen)

Introduction: The earliest anatomical descriptions about the cutaneous ligaments of the finger go back for centuries. Till now, no unequivocal description exists about anatomical location, function and movement of the ligaments of Grayson and Cleland. The purpose of this anatomical study was to re-evaluate the anatomy and function of these cutaneous ligaments.

Methods: We micro-dissected twenty fingers from twenty fresh frozen human cadaver hands. Human cadaveric hands preserved with the Thiels method were dissected for a better understanding of the dynamics. During dissection the following measurements were taken for Cleland and Grayson: location, width of origin and insertion, and the length between origin and insertion for all different bundles.

Results: Grayson's ligament appeared to be a network of fibres originating from the flexor tendon sheath; its insertion at the contra lateral side in different planes into the skin, volar to the neurovascular bundle. Functioning as a stabilizer of the skin. For Cleland's ligament we found four pairs, transverse and oblique orientated ligaments, originating from the proximal phalanx as well as from the middle phalanx. Each ligament consisted of different layers originating from the tendon sheets and periosteum. Its function is to prevent the skin from bagging, protection of the neurovascular bundle and creating a sliding path for the lateral slips of the extensor tendon.

Conclusion: Grayson's fibres appeared to be important in movement of the skin and its contribution to a solid grip. The position, orientation and dynamics of Cleland's ligament gave a clear insight in its function.

2 A rare case of aggressive digital papillary adenocarcinoma

Dr S Coulson, Dr K Dunn (Sheffield)

Case: We report the case of a seventy-year-old Caucasian gentleman who presented with a painful 2cm swelling in the nail bed of the right middle finger. Following MRI and USS the swelling was thought to be either an epidermoid cyst or glomus tumour. A plain chest radiograph was normal. Following amputation of the right middle phalanx, histopathology confirmed aggressive digital papillary adenocarcinoma (ADPAca) which was only 0.7mm from the nearest resection margin. Further surgical treatment to ensure an adequate resection margin was offered but declined. Approximately eighteen months later the patient presented with a mass in the right axilla. A plain chest radiograph showed pulmonary metastasis. An axillary clearance was performed for local control and one of 10 nodes revealed metastatic disease. The patient remains asymptomatic from the pulmonary involvement.

Discussion: ADPAca is a rare neoplasm of the eccrine sweat glands, which commonly presents as a slow growing mass between the nail bed and distal interphalangeal joint. The disease is classically aggressive with a 14% chance of metastatic spread. Lung tissue is the commonest site for metastasis, with other sites including lymph nodes, brain, skin, bone and kidneys. The chance of recurrence is 50% with no or sub-optimal treatment, which reduces to 5% following removal with adequate resection margins.

Conclusion: This case highlights that a rare malignant tumour, presenting with a swelling of the digit, can mimic benign conditions. ADPAca must be treated aggressively, providing clear resection margins as well as frequent and long-term follow-up.

3 Isolated tuberculosis of the wrist - A rare case of extrapulmonary tuberculosis

Dr M A Mussa, Mr E O'Connor, Mr S Waterston, Mr F Iwuagwu, Mr M Taylor (Chelmsford)

Introduction: Extrapulmonary tuberculosis involvement of the musculoskeletal system is uncommon and involvement of wrist or carpal bones is a rare presentation. The diagnosis may be easily delayed because of its non-specific clinical signs resulting in progression of disease and more advanced disability.

Material: The authors report a new case of tuberculosis of wrist joint in a 24-year-old male without concomitant pulmonary tuberculosis or documented immunodeficiency.

Results: The patient underwent operative washout and focused antibiotic therapy and was effectively treated. Pain, swelling and movement at the wrist improved. He is currently still undergoing regular hand therapy.

Conclusions: The disease may mimic inflammatory arthritis and physicians should have a high index of suspicion when dealing with refractory long standing bony swellings.

4 **A unique case of transcapoid transcapitate perilunate dislocation in an adolescent: Case report and literature review**

Dr K Osman, Dr F Momoh, Mr A Ruiz (London)

Introduction: Difficulty in the early recognition of perilunate fracture dislocations often results in delayed surgical treatment and poor outcomes. We describe a unique case of transcapoid-transcapitate perilunate dislocation with a review of the relevant literature, challenging the concept of 'naviculocapitate syndrome'.

Methods: A MEDLINE search of case reports containing 'perilunate dislocation' and 'capitate' yielded fifteen results of which 5 involved capitate fractures. None involved complete displacement of the capitate fragment.

Case Report: A fourteen-year old boy presented with a displaced left scaphoid fracture after a fall from a height. He underwent a volar approach open reduction internal fixation with a Herbert screw. Post-operatively, plain radiographs revealed discontinuity of Gilula's arcs prompting further imaging. A CT scan with 3D reconstruction views revealed a complete transverse capitate fracture with ejection of the proximal fragment into the carpal tunnel. A volar approach through the carpal tunnel revealed a capitate fragment devoid of ligamentous attachment, which we reduced and fixed with two Kirschner wires. No loss of function was observed at ten weeks with 90° of wrist flexion/extension and no radiographic evidence of avascular necrosis (AVN).

Conclusion: This case highlights the importance of careful evaluation of radiography and early utilisation of CT or MRI. When recognised, urgent open anatomical reduction and internal fixation with an anterior approach is an effective management plan. There may be cause to reconsider the risk of AVN in displaced capitate fractures, considering the lack of signs of AVN in this extreme case.

5 **Use of botulinum toxin in complex regional pain syndrome in the hand**

Miss L Ovens, Mr D Dewar (London)

This is the first report of the use of botulinum toxin injected into the hand to treat complex regional pain syndrome (CRPS). Botulinum toxin has been shown to improve pain in Raynaud's syndrome, carpal tunnel syndrome and CRPS of the lower limb. Botulinum toxin has also been shown to act on pain neurotransmitters directly.

A forty-year-old man was referred to us with bilateral CRPS after falling onto his hands. Fifty units of Botox® were injected into the carpal tunnel and 50 units around the digital neurovascular bundles of the left non-dominant hand. Hand assessments were performed before injection, and weekly for six weeks post-injection. The dominant hand acted as a control.

Total active movement did not change significantly. A steady improvement of power grip strength in the left hand was shown. Power in his left hand was greater than the right, despite him being right handed. He felt the injection was beneficial.

Botulinum toxin may have improved the signs and symptoms of CRPS in the hand due to its combined effect on the vascular and nervous systems. Botulinum toxin may block the self-per-

petuation cycle of pain and sympathetic stimulation by blocking neurotransmitters and warrants further studies on CRPS.

6 Spontaneous regression of digital enchondroma
Miss N Alam, Mr A Mishra, Mr I Khan (Liverpool)

Enchondromas are rare benign cartilaginous bone tumours which are a frequent cause of pathologic fractures. When associated with a pathologic fracture, in most cases the fracture is allowed to heal with closed treatment. Curettage and bone grafting is then required. Spontaneous resolution of the enchondroma following fracture healing is not expected to occur.¹

Materials and Methods: We discuss an interesting case of a digital enchondroma in a forty-nine year old self-employed patient who presented with a painful swelling on the tip of his left middle finger. X-ray showed an enchondroma in the distal phalanx with an associated pathologic fracture. The patient declined surgery due to the nature of his employment. He was monitored with serial X-rays which initially showed no changes. But two years after his initial presentation he demonstrated both clinical and radiological resolution of the enchondroma.

Result: The patient has got a painless left middle finger with no palpable lesion and is continuing to work with no residual problems.

Conclusions: Complication rate of enchondroma curettage is considerable.² Malignant transformation of a solitary enchondroma to a chondrosarcoma is rare. Regular radiological follow-up of even symptomatic enchondromas may therefore be a reasonable option.

References:

1. Kuur E, Hansen SL, Lindequist S. Treatment of solitary enchondromas in fingers. *J Hand Surg Br* 1989; 14: 109–112.
2. Müller PE, Dürr HR, Wegener B, Pellengahr C, Maier M, Jansson V. Solitary enchondromas: is radiographic follow-up sufficient in patients with asymptomatic lesions? *Acta Orthop Belg* 2003; 69: 112–118.

7 Management of the Boutonniere deformity associated with Dupuytren's disease - Release of the oblique retinacular ligament
Mr D Avis, Mr D Hargreaves (Southampton)

Introduction: A Boutonnière deformity is a rare but well recognised complication of Dupuytren's disease. The treatment options are controversial and there is little consensus regarding the pathophysiology and consequential surgical management of such deformities.

Methods: We have identified and reviewed thirteen patients (14 digits) with a Boutonnière deformity secondary to Dupuytren's disease, operated on by a single consultant hand surgeon over a ten-year period from 2001–2011. Two patients had true Boutonnière deformities and had treatment with lateral band relocation, one with an associated Fowler tenotomy. The other eleven digits had release of the oblique retinacular ligament (ORL).

Results: The average pre-operative PIPJ contracture was 87° fixed flexion deformity. In all but one case, DIPJ flexion, with the PIPJ maintained in extension was restored following release. The case of incomplete correction was due to DIPJ degenerative changes. A PIPJ release was required in three cases. This resulted in full PIPJ deformity correction in 93% of cases. This then returned to an average 39° fixed flexion deformity by six months.

Conclusions: We feel that this is a good result in a prognostically poor group of patients. We believe the contracture of the ORL is an important cause of this deformity which needs to be surgically addressed in order to maximise potential correction.

8 The involvement of the cutaneous ligaments of the finger in Dupuytren's disease
Dr R Zwanenburg, Dr M Horst, Professor P Werker (Groningen)

Introduction: Involvement of the cutaneous ligaments of the finger in Dupuytren's disease has always been a topic of discussion. New findings about the anatomy of the ligaments of Cleland and Grayson provided a stepping-stone to new insights into the patho-anatomy of Dupuytren's disease. The purpose of this study was to clarify the relationship between the cutaneous ligaments of the finger and the phenotype of Dupuytren's disease.

Methods: We included forty-seven fingers that were primarily affected by Dupuytren's disease. Through photography before and during fasciectomy, the phenotype of Dupuytren's disease was documented. Additional information was collected through a checklist and a schematic representation of the pathological cord in the finger.

Results: Our results show Dupuytren's tissue present at the site of Cleland's ligament, dorsal to the neurovascular bundle at different levels. The network of fibres of Grayson shows a change in pattern; with an increase of the flexion contracture the normal "inverted V" pattern changed into a "V" pattern ($P < 0.005$). Involvement of Grayson's fibres was also found in a so-called "oblique cord", this cord always shows an increasing extension deficit.

Conclusion: This study gave us a better insight into the involvement of the cutaneous ligaments of the finger in the patho-anatomy of Dupuytren's disease. The ligaments of Cleland are involved, however its role and influence is still unclear. The involvement of Grayson's network of fibres was clearly visible, a possible influence on the flexion contracture cannot be excluded.

9 Re-operation after open fasciotomy for Dupuytren's disease: A five-year review of 1,114 consecutive cases

Miss C J Stewart, Mr I Ahmed, Mr L Suleman-Verjee, Mr G Hooper, Ms D M Davidson (Edinburgh)

Introduction: In recent years there has been considerable interest in the results of needle fasciotomy in the treatment of Dupuytren's disease, but little has been written about the results of treatment by open fasciotomy. We have reviewed a series of 1,114 consecutive open fasciotomies, with the objectives of ascertaining re-operation rate with a minimum five-year follow-up, and of studying the results of secondary surgery.

Methods: Review of theatre coding data allowed identification of all open fasciotomies performed by a single consultant between January 2000 and January 2005. A retrospective review of hospital records was performed for patients identified as undergoing re-operation before 2010.

Results: 1,114 open fasciotomies were performed by a single surgeon using an unmodified technique over a five-year period. One hundred and twenty-four patients underwent re-operation of the digit(s) (11.5%). Review of hospital records was possible for ninety-seven of these patients (144 digits), with a mean follow-up of 7.2 years (range 5–10 years). Re-operation consisted of repeat open fasciotomy (n=19), fasciectomy (n=47) and dermofasciectomy (n=78). Mean time to re-operation was 44.5 months (range 8–99 months). Mean pre-operative total extension deficit was 88° (range 30–180°), with intra-operative correction to a mean of 9.5° (range 0–45°).

Conclusion: There is no standard definition for recurrence after Dupuytren's surgery. We have looked at the rate of revision surgery after open fasciotomy, in a relatively fixed population serviced over a ten-year period by a single hand surgeon. A low re-operation rate has been identified, with good intra-operative correction achieved by secondary surgery.

10 Nailbeds: A problem worth splinting?

Mr T Bragg, Mr G Davis (Oxford)

Background: Nailbed repairs are one of the most frequently performed plastic surgery operations. A paucity of information exists to drive management. We aimed to look at the practice of splinting the nailbed post repair, rejected by some due to fears over increased infection rates.

Methods: We sent out a questionnaire survey to one hundred and seventy-eight patients following nailbed repair. This gathered detailed data on mechanism of injury, complications from surgery and outcome in terms of function and appearance. Patients were asked to rate their overall satisfaction with comparison to the contralateral undamaged digit, with a focus on the quality and adherence of the new nail.

Results: 84% of patients had a crush type injury with 57% patients sustaining a fracture. 38% of patients had a course of oral antibiotics with only 58% completing the course. There was a 92% satisfaction rate overall with only one (1%) patient requiring revisional surgery. 49% of patients had their nail replaced as a splint, 10% patients had a synthetic splint. Adherence of the nailplate to the nailbed was highest (94%) in the nail replacement group and statistically significantly lower (53%) in the exposure group.

Conclusions: This study strongly advocates the use of splints (autologous or synthetic) as an adjunct to nailbed repair. There seem to be advantages to the specialist epithelium at this location in terms of adherence to the nailplate giving both an aesthetic and functional advantage. Previous concerns over infection were not supported by this study.

11 Buried Kirschner wires in hand trauma: Do they reduce infection rates and is it worth the extra cost?

Mr T Koc, Mr S Aleksyeyenko, Mr J Ahmed (London)

Introduction: There has been little research to date comparing the rate of infectious complications between buried and percutaneous Kirschner wire (K-wire) use in surgery for fractures of the hand. In a cash limited health system, the additional cost of removing K-wires should be justified by a demonstrable reduction in the frequency and/or severity of infectious complications.

Methods: We prospectively collected data on injury and patient related factors, peri-operative factors, aftercare and details of any infective complications including Oppenheim grade.

Results: We observed seven (10%) infections in 70 patients who had wires left protruding through skin and three (9%) infections in 34 patients who had wires buried deep to skin. In the group where wires were left protruding, four grade I, two grade II and one grade V infections were observed, whereas in those with buried wires, there were two grade I and one grade IV infectious complications. There was no statistically significant difference in the rate of infectious complications between cases using buried versus percutaneous K-wires. Cost analysis showed that the overall cost per patient was £235.51 for use of buried wires and £90.80 for use of percutaneous wires.

Conclusions: Burying K-wires, as opposed to leaving them proud, did not significantly reduce the frequency of infectious complications. Burying K-wires more than doubles the cost per patient. Overall, it is difficult to justify the additional cost of burying K-wires.

12 Radiological assessment of screw lengths between the variable and the fixed angle volar locking plates for distal radius fractures

Mr L Al-Mouazzen, Mr J Hambidge (Romford)

Introduction and Aims: The percentage of subchondral bone unsupported by screws was measured in two different volar plates used to internally fix intra-articular distal radius fractures, the Synthes volar locking variable angle plate and the DePuy DVR plate aiming to show which type of plate provides better support for the subchondral bone in the distal radius fractures with better anchorage of the dorsal cortex fragments.

Methods: We retrieved forty cases which had open reduction and internal fixation over an eight-month period (20 each). On the lateral view of the post-operative films, we measured the width of the distal radius metaphysis (b) and the length of the subchondral bone not supported by a screw (a). The value of (a/b) represents how much of the sub-chondral bone not supported by the metal in relation to the width of the distal radius metaphysis.

Results: The average of unsupported subchondral bone was 13% for the AO Synthes plate group and 27% for the DePuy DVR plate group ($p < 0.0001$).

Conclusion: Both the Synthes variable-angle plate and the fixed-angle DVR plate adopt a similar design philosophy that uses locking buttress pins distally to provide subchondral support of the distal radius. To date no studies have compared the two plates in terms of the screw placement in the subchondral bone. We conclude that the variability in placing the screws in the Synthes plate allows for screws to be near the perfect measurement that provides the maximum rigidity for the fixation construct.

13 Effect of osteoporosis on recovery of wrist function in distal radius fractures

Dr W S M Williams, Mr C Williams, Professor C Hutchinson, Mr J Andrew (Bangor)

Introduction: Osteoporotic patients sustaining a fracture frequently ask whether this affects fracture healing and outcome but the answer to this is not clear. Previous reports about this are very limited. We studied recovery after distal wrist fracture and related it to the BMD of the uninjured wrist.

Methods: Twenty-four patients sustaining a dorsally displaced distal radial fracture requiring intrafocal wire fixation were evaluated prospectively. Wrist function was measured with using PRWE, wrist ROM and grip strength. All variables were measured at six weeks, 3 months and 6 months. BMD in fractured and non-fractured wrists were measured at 6 weeks using pQCT.

Results: We compared grip strength and PRWE in patients with above and below the mean value of opposite wrist BMD. Patients with below mean BMD scores had better PRWE values at six months ($p < 0.05$). Patients with below mean BMD (mean age 70) had a mean PRWE six months post fracture of 8.83 whereas a patient with above mean BMD (mean age 62) had a mean PRWE of 33.91. There was no significant difference between proportion of grip strength recovered or PRWE at other time points.

Conclusion: This data suggests that there is minimal effect of osteoporosis on recovery of wrist function after distal radial fracture. Elderly patients with a lower BMD have somewhat better recovery than younger patients with a higher BMD. This may be due to the higher initial injury energy and associated soft tissue wrist injury in non-osteoporotic patients.

14 Stiff wrists do badly: Effect of early range of movement on functional outcomes of wrist fractures

Dr W S M Williams, Mr C Williams, Professor C Hutchinson, Mr J Andrew (Bangor)

Introduction: The early range of movement following distal radial fracture varies surprisingly, but it is not clear how this influences subsequent functional recovery.

Methods: A cohort of thirty-five patients with displaced distal radial fractures who underwent intrafocal wiring fixation was followed prospectively for 6 months after fracture. Patients were treated in plaster for four weeks; wires removed at 5 weeks and were assessed at 6 weeks, 3 and 6 months respectively for grip strength, ROM and PRWE. All X-rays were acceptable at six weeks.

Results: We found progressive recovery in the injured wrist, grip and movement recovery was still incomplete at six months. We examined the effect of the arc of flexion/extension at six weeks on the proportion of grip strength recovered (compared with the uninjured wrist) and the PRWE of the injured wrist. The mean flexion/extension arc at six weeks was 65°. Patients with a lower

arc than 65° had significantly worse recovery of grip at three and six months ($p < 0.01$) and worse PRWE at 3 months ($p < 0.05$).

Conclusion: The finding that flexion/extension at six weeks is strongly predictive of grip recovery at 3 and 6 months suggests that intra articular soft tissue damage due to the fracture may determine the rate of recovery of grip. We conclude that specific attention should be paid to patients with poor movement at an early stage after wrist fracture, both by provision of additional therapy for individual patients and study of the mechanisms underlying this pathology.

15 Scaphoid fracture in the elderly: A review

Mr A Alsawadi, Mr J Stanton (Colchester)

Introduction: Scaphoid fractures represent about 5% of all orthopaedic fractures and are the most common of all carpal bone fractures. The classical teaching, in fact, is that scaphoid fractures typically occur in the age between ten and 60 years (or 70 years in other sources). There are few epidemiological studies of scaphoid fractures in the literature with little variation in the results, but, to our knowledge, the incidence or the prevalence of scaphoid fractures in the elderly population is not focused on and not studied or explored.

Objectives: The aim of this review is to identify, from the available data, how common scaphoid fractures are in the elderly population (over 70 years old).

Methods: We reviewed the literature for any available epidemiological studies of scaphoid fractures and searched the available data of scaphoid fractures in the elderly population. We also searched for case series and case reports which have relevant data on the subject.

Results: Four epidemiological studies, two case series, and one case report are included. We discuss the available data in these articles and conclude that scaphoid fractures in the elderly, although rare, have been reported, but there are not enough epidemiological studies to draw figures.

Conclusion: Scaphoid fractures in the elderly, although rare, have been reported. Ignorance of this could result in missed fractures in the elderly. The classical teaching of the subject usually ignores this segment of the population. Therefore, we encourage epidemiological studies of scaphoid fractures in the elderly, which are severely lacking.

16 A versatile and less invasive approach to distal radius fracture fixation

Dr M Strassmair, Dr S Moran (Starnberg, Germany)

Introduction: Today, many people remain physically active well beyond their sixth decade of life. This group is at increased risk for sustaining a distal radius fracture and their expectations for treatment and return to function are very high. A new intramedullary fracture fixation device has been developed to address complications typically associated with plate fixation.

Methods: A prospective case study was performed. Following provisional reduction, a small incision and a 5mm diameter cortical hole are created on the lateral-proximal aspect of the radius. An expandable broach is inserted into the medullary canal and used to prepare the metaphysis. The device is a nitinol scaffold, which is introduced into the canal in a compressed state and then expands to fill the prepared space. Cannulated bone screws are inserted percutaneously through fracture fragments and into the expanded scaffold to provide stable fixation. Screw quantity and orientation can be tailored to the individual fracture pattern. Patient outcome was assessed based on serial radiographs, adverse event reporting and DASH scores.

Results: Twenty-two patients have undergone surgery, with post-implant time ranging from 1–60 weeks. Review of radiographs at subsequent follow-up revealed no loss of reduction compared to the immediate post-operative images. DASH scores for twelve patients at 12 week follow-up all exhibited improvements with a mean score of 22.0 points.

Summary: Early clinical experience with this new technique is promising. This study demonstrates the technique's ability to deliver stable fixation through a tissue-preserving approach and maintain reduction throughout the healing phase.

17 Standardised photographic views for documenting clinical results

Dr M F Freshwater (Miami)

Hypothesis: No uniform standards exist for documenting clinical results photographically for either publication or presentation. No mention of such standards exists on the BSSH, ASSH, Journal of Hand Surgery (European) or the Journal of Hand Surgery (American) websites. Until videography becomes a routine part of both online publications and presentations, valid photographic documentation of results is vital. By not using standard and reproducible views, it is possible to produce misleading results even without resorting to conscious digital manipulation.

Methods: Examples of misleading photographs from texts and journals are given showing how the casual observer can be misled by presenters and authors:

1. Not showing views in all relevant anatomical planes
2. Showing passive rather than active motion
3. Allowing "trapping" by patients

We have developed a set of recommended views that are based upon the readily accessible drawings in the AMA Guides to the Evaluation of Permanent Impairment.

Results: A more accurate picture of clinical results is obtained with still photographs in multiple planes demonstrating active motion when patients are photographed with reproducible views that are based upon the drawings in the AMA Guides.

18 The range of movement of the thumb

Mr M Barakat, Ms J Taylor, Mr J Field (Gloucester)

A prospective cohort study was performed looking at one hundred consecutive individuals without thumb pathology to determine ranges of flexion and radial abduction, palmar abduction, retro position, and opposition of the CMCJ. Ranges of interphalangeal movements were also measured in order to obtain the normal ranges of thumb movement of each individual. Inter-reliability and intra-reliability correlation was measured.

The mean age was twenty-six (range of 18–37) with 62 female individuals. The mean range of movement of the IPJ was flexion of 88° (80°-90°) and extension of 12° (0°-45°). The mean range of movement of the MCPJ was flexion of 60° (43°-70°) and extension of 8.1° (0°-15°). The mean range of movement of the CMCJ was antepronation of 61.2° (50°-71°), retropronation of 31.1mm (25-38mm), radial abduction of 62.9° (53°-71°) and opposition Kapandji grade 9 (Grade 9–10).

The mean inter-reliability correlation coefficient was 0.82 ($p < 0.01$) while the mean intra-reliability correlation coefficient was 0.93 ($p < 0.01$). There was negative correlation identified between IPJ extension and MCPJ extension (-0.50) and between CMCJ radial abduction and MCPJ extension (-0.60).

Having established the normal ranges of movements for the thumb joints and shown that our measurement methods are reliable and reproducible, we have identified that if one joint of the thumb moves less, this lack of movement is compensated for by increased range in the other joints.

19 Ulnar nerve compression at the cubital tunnel in a tetraplegic patient following biceps to triceps transfer - A case report

Miss M Mughal, Mr P Mathew, Dr H Hastings (London)

We present an unusual case of ulnar nerve compression at the elbow in a tetraplegic patient post-operatively after tendon transfers to enhance upper limb function.

In the majority of tetraplegic patients with high-level injury, where Functional Electrical Stimulation is anticipated, it should be recognised that the medial route of biceps to triceps transfer also carries risk of “silent” compression of the ulnar nerve (which is often the only functioning nerve). These can exhibit as failure of the FES system to successfully stimulate ulnar innervated musculature post-transfer.

Restoration of upper extremity function especially the ability to extend the arm in a tetraplegic patient is important to allow wheelchair mobility, independent transfers and for pressure relief maneuvers. Biceps to triceps transfer via the lateral route (Friedenberg, 1954) was first described in a case of poliomyelitis. Zancolli (Zancolli EA, 1991) and others have described cases of radial nerve injury when the transfer is done via the lateral route. Revol (Revol, et al., 1999) described the use of the medial route as an alternative to avoid the complication of radial nerve injury.

In transfer of the biceps to triceps via a medial approach care must be taken to be sure the transfer is not directly compressing the ulnar nerve. This may require routing the transfer deep to, rather than superficial to the ulnar nerve in its medial route. In-situ decompression of the ulnar nerve with assessment of the need for transposition is also recommended when performing biceps to triceps transfer via the medial route.

20 A survey of practices in East Anglia relating to carpal tunnel decompression

Mr P Robinson, Mr P Crossman (Ipswich)

Introduction: The aim of this study was to assess the usual practices of hand surgeons in East Anglia when undertaking carpal tunnel decompression (CTD), to identify extent of common practice and variations.

Materials and Methods: Members of the East Anglian Hand Club (n=24) were sent an email survey consisting of thirteen questions on consent, anaesthetic use and administration, operative details e.g. use of tourniquet, incision, neurolysis, wound closure, dressings, follow-up and audit of practice.

Results and Discussion: The initial response rate was 67%. There were areas of common practice – discussion of certain complications in the consent process, lack of use of topical anaesthetic, use of a blue 23 gauge needle for injection, concentrating on complete release of the retinaculum at operation – although there may be evidence to support modifications in some of these e.g. concerning anaesthetic injection. There were other areas of variation which divided the group: anaesthetic agents used, use of adrenaline, or of tourniquet, suture material, dressings, post-operative advice, follow-up arrangements and audit of practice. It may be that some variations in practice reflect the fact that similarly good outcomes can be achieved by different means, but others may have some impact on patient experience, possibly quality assurance and costs.

Conclusion: Although CTD is a particularly frequently performed procedure and most surgeons will have good reasons for their approach, there seems to be scope for consideration of the evidence base, refinement of practice and perhaps cost efficiencies.

21 The effect of perfusion pressure at different angles of upper limb elevation

Ms G Darmanin, Mr M Jaggard, Professor J Nanchahal, Mr A Jain (London)

Background: It is common practice to elevate the upper limb post-operatively to reduce oedema. However, elevation may be counterproductive as it may reduce perfusion pressure. There is no clear data on the optimal peri-operative position of the upper limb after hand surgery.

Methods: Perfusion of the upper limb at different arm and forearm positions was assessed in twenty-five healthy subjects by measuring haemoglobin (Hb) concentration, blood flow and oxygen saturation (SO₂) using the “O₂C” machine (LEA Germany). This was repeated under ischemic conditions (using a tourniquet) and on tourniquet release (reperfusion).

Results: On upper arm elevation blood flow (150 ± 13) and Hb (50 ± 9) significantly decreased ($p=0.0001$) when compared to heart level (flow 180 ± 13 , Hb 62 ± 15). On dependency there was a reduction in flow (161 ± 14 , $p=0.03$) and an increase in Hb (73 ± 16 , $p=0.0001$). SO₂ decreased on both elevation ($p=0.0001$) and dependency ($p=0.0005$). On forearm elevation, flow increased more at 45° (104 ± 64 , $p=0.02$) than 90° (99 ± 58 , not significant) when compared to heart level (83 ± 44). Hb levels decreased significantly ($p=0.0001$) at both levels of elevation. On tourniquet inflation readings of flow demonstrated a dramatic fall at all limb positions. When deflated, there was a 44%–89% rebound increase in flow, whereas SO₂ and Hb returned to pre-tourniquet levels.

Conclusions: Optimal perfusion is with the upper arm at heart level and forearm at 45° as suggested by markers of arterial flow (flow and SO₂) and venous congestion (Hb).

22 Electrical hand burns: Ten-year review

Miss A Hay-David, Mr Z Shariff, Mr J Rawlins (Wakefield)

Electrical injuries are relatively uncommon. Multi-system injury is frequently observed, either directly related to electrical shock or secondary to concurrent trauma (Lederer W). Electrical injuries to the extremity can result in significant local tissue damage and systemic problems (Arnaldo). Electrical burns of the upper extremity, particularly high-voltage injuries, are becoming more prevalent in today's society and are often devastating to the patients' appearance and functionality. We have reviewed outcome of electrical hand burns of patients treated at the Yorkshire regional burns unit in the last ten years.

Material and Methods: This is a retrospective audit. All patients treated for electrical burns between 2001 and 2011 were extracted from the burn database. Patients with hand burns were included in the study. The demographics, pattern of burn and outcomes were noted.

Results: A total of thirty-two patients with electrical burns were treated in the last ten years at the Yorkshire Burns Unit. Seventeen of these patients had burns on the hands. Patients' age ranged from 22 months to 74 years. Five patients were in the paediatric age group. Out of these only four needed surgery in the form of debridement and skin graft. One had amputation of the hand and one needed delayed reconstruction with a local flap.

Conclusion: Burns of the hands account for 50% of electrical injuries. As these are usually injuries at home (low voltage) most of them are managed conservatively. When the injury is from high voltage this may end in amputations.

23 The activities and roles of hand therapists in Pinderfields Hospital, Wakefield

Miss H Douglas, Mr M Gregson, Mr S Southern (Wakefield)

Introduction: Hand therapy is an integral part of any traumatic hand injury or elective hand operation, whether the management is non-operative, pre-operative or post-operative. In the Pinderfields Hand Unit the role of the occupational therapist and physiotherapist has expanded to form a more global practitioner role of hand therapist, which provides a wide and essential range of services to patients, many of which go unrecognised. We wished to document all activities the therapists provide, many of which are provided simultaneously.

Methods: To formally evaluate the different activities hand therapists in our unit provide, total therapist activity was monitored over a two-week period and each individual patient-based activity performed was recorded.

Results: The table below outlines the various activities performed by hand therapists in Pinderfields Hospital over the study period.

'Traditional' Therapy activities	Wound Activities	Extended Role activities
Physical therapy	Wound care/assessment	Fracture assessment
Work-related Occupational therapy	Dressing changes	Referral to other practitioner
Acts-of-daily-living Occupational therapy	Removal of sutures	Fitness for work certification
Splintage	Graft checks	Discharge from service
Pressure therapy/garments	Scar management	Psychotherapy

Conclusions: In Pinderfields Hospital the hand therapists provide a global service that extends beyond the traditional role of occupational therapist or physiotherapist, extending to services previously the responsibility of nursing or medical practitioners. These activities are supported by weekly MDT hand clinics and fracture assessment clinics. By working closely as a hand unit, we can provide continuity of care in a supported and MDT environment to benefit therapists, practitioners and patients.

24 First carpometacarpal joint arthroplasty with ligament reconstruction and tendon (FCR) interposition: A twelve-year follow-up

Miss L Banks, Mr M Hakimi, Mr E Jesudasan, Ms J Wood, Mr K Sharpe, Mr M Srinivasan (Manchester)

Introduction: First carpometacarpal joint (CMCJ) arthritis has been shown to do well with arthroplasty surgery using ligament reconstruction and tendon interposition (LRTI), but few long-term follow-ups have been reported. We present a long-term follow-up of twenty-seven first CMCJ arthroplasties with LRTI (flexor carpi radialis tendon [FCR]).

Methods: Patients were followed up prospectively with functional and outcome scores (DASH and Mayo), range of movement (metaphalangeal, interphalangeal, Kapandji scoring, hand spans), pain (0 to 10), grip strength (gross, key, tripod, pinch), carpal height and translation (radiographically) and patient satisfaction (0–10) were all assessed.

Results: Median follow-up was forty-eight months (range 22–144). Our results show low complication rates (11%) with high patient satisfaction (10), low pain scores (1) and excellent range of motion (Kapandji: 10). Carpal height (0.55cm) and translation (0.38cm) were within the range expected in a comparative cohort. Gross strength was near normal in a comparative cohort (73%). Mayo scores were satisfactory/good in 74%.

Discussion: Our patients have one of the longest follow-up for LRTI when compared with previous literature. Results illustrate that carpal height and translation are preserved within limits that would be expected and range of motion are excellent in the long-term. Gross strength is similar to normative values. We would suggest that in the long-term carpal height is preserved in this group of patients using a FCR LRTI. We believe that this is a good option for patients with end-stage first CMCJ arthritis, giving them good long-term satisfaction, range of motion and grip strength, whilst maintaining carpal height and translation.

25 Hand injuries in cricket - Should fielders wear protective gloves?

Mr J Russell, Miss J Hughes, Mr S Lee (Bristol)

Aims: Although cricket is seen as a gentleman's game, it is among the top ten sports most likely to result in injury. Yet typically, the only players allowed to wear protective gloves are the batsman and wicket keeper. This study aims to analyse the pattern of hand injuries occurring at the amateur level, and in doing so, assess whether more can be done to improve player safety.

Methods: A prospective analysis was performed of all cricket hand injuries presenting to the plastic surgery unit at Frenchay Hospital, Bristol, during the summer months of 2010.

Results: There were a total of twenty-eight episodes in 27 patients, including 26 amateur players and one professional, with a mean age of 33 years (range 13–63 years). 78% of injuries were sustained whilst fielding (n=22), with a small proportion of batsmen and wicket keepers being injured (n=5). Only these five players were wearing protective gloves at the time of injury. Most sustained their injuries through a direct blow or axial load to the fingers (n=22), with the ulnar digits and thumb most commonly affected. There were twenty fractures, eight dislocations, and 25 were associated with soft tissue injury. The distal phalanx was the most frequently injured site (n=11), followed by the distal interphalangeal joint. However, most of the injuries were suitable for conservative management, with only three patients requiring bony fixation.

Conclusion: Our study highlights that hand injuries are common amongst amateur cricket players, and that a lack of protective gloves may be an important factor.

26 Sports induced scaphoid dislocation in a young adolescent

Mr S J Rhee, Mr D Barlow, Ms K Lewis (Oswestry)

Introduction: Carpal bone dislocations usually present as lunar or peri-lunar dislocation. Isolated scaphoid dislocations are very rare and have only been reported sporadically in the English literature. Such dislocations are almost always associated with another accompanying injury at the wrist, and much of the literature has focused on complex scaphoid dislocations associated with high velocity road traffic accidents.

Aims: We aim to discuss a case of isolated scaphoid dislocation following a rugby tackle, and hope to highlight this rare injury as an important differential diagnosis of acute sports wrist injuries.

Materials and Results: The unusual clinical presentation and radiological investigations of a young adolescent following a rugby tackle prompted early intervention. The scaphoid was openly reduced using a dorsal approach to the wrist, with scapholunate ligament reconstruction and scapholunate and scaphocapitate K-wire fixation for stability. Post-operatively, the patient was back to normal activities, with almost full range of wrist motion. At thirteen months follow-up, the wrist was pain free with near normal grip function. DASH score was 29.2; VAS score was 0 at rest.

Conclusion: Due to the rarity of such carpal injury, it can be easily over-looked unless it is specifically sought for. The mechanism of injury, clinical examination and plain radiographs demonstrating a dislocated scaphoid should prompt a surgeon for early open reduction and stabilisation. Reconstruction of the inter-carpal stabilisers can result in good functional outcome.

27 Endoscopic cubital tunnel decompression - A modified technique

Mr N Kain, Mr C Bainbridge (Derby)

Introduction: Over the last ten years, endoscopic cubital tunnel decompression (ECuTR) has grown in popularity, with the minimally invasive technique achieving better symptom relief and less scarring compared to open techniques.¹ We present a new suprafascial technique, which not only allows more extensive ulnar nerve decompression as current techniques, but also protects against injury to the medial cutaneous nerve.

Technique: A 3cm transverse incision is made just distal to the elbow, using the medial epicondyle and olecranon as landmarks. Unique to this technique is the suprafascial plane and custom instrumentation (Tulip[®]) used to approach the ulnar nerve. This allows direct visualisation and release of constricting structures, thus facilitating an extensile approach to the decompression.

Methods: A retrospective analysis of case notes was carried out on all patients who underwent endoscopic cubital tunnel decompression over a four-year period (2008 -2011). Data regarding the pre-operative nerve conduction studies, surgical technique and complications were extracted.

Results: One hundred and twenty-one patients underwent endoscopic cubital tunnel decompression over the four-year period. Over 90% of patients had ulnar nerve compression confirmed on nerve conduction studies. Patients were discharged at six-week follow-up if symptoms had

improved. Improvement/resolution of symptoms was present in 90% of cases. Complication rate is comparable to current literature.

Conclusion: The senior author's endoscopic technique for cubital tunnel decompression is successful and satisfactory, allowing direct visualisation of the ulnar nerve throughout the procedure.

References:

1. Hoffmann R, Siemionow M. The Endoscopic Management of Cubital Tunnel Syndrome. *J Hand Surg Br* 2006; 31: 23.

28 Best of both worlds? A novel strategy combining K wires and ORIF in the management of a trapezium fracture

Mr R Kallala, Mr D Nikkhah, Mr J Rodrigues, Mr W DeJager (Bradford)

Introduction: The trapezium is the third most commonly fractured carpal bone, yet existing literature guiding management is limited to case reports and series. Poor outcomes may result in post-traumatic arthritis. We report a challenging case managed using a novel operative strategy, and review the literature describing trapezium fracture treatment.

Case: A seventeen-year-old male presented with isolated right wrist pain after falling down a flight of stairs. Radiographs revealed a complex intra-articular fracture of the right trapezium. CT demonstrated fracture extension into the thumb carpo-metacarpal joint, with 1cm fragment displacement.

As K-wires may not compress the fracture, but the degree of comminution may render ORIF difficult, a novel strategy was employed. A volar approach to the trapezium was used and the thenar muscles elevated. Two parallel K-wires were passed from the thumb metacarpal to the index metacarpal. This prevented loading of the comminuted trapezium fracture during initial fracture healing. The fracture was reduced and lag screw fixation performed. Post-operatively, the patient recovered well: at four-month follow-up, he was back at work pain-free, with nearly full range of movement.

Literature Review: OVIDMedline was searched and abstracts reviewed. Thirteen publications describing trapezium fracture management were identified. The largest series (Pointu and colleagues) comprised thirty-four patients and concluded that operative management is indicated in displaced or unstable fractures. Managing trapezium fractures using K-wires alone is described, however some studies suggest lag screw fixation may achieve better results. This novel method combines K-wires limiting axial loading of fragments, with a lag screw achieving fracture compression.

29 Patient satisfaction with hand surgery using local anaesthesia with adrenaline: A prospective audit

Mr N Probert, Mr B Fischer, Mr J Spibey, Mr S Hodgson, Mr P Wykes (Bolton)

Introduction: Recent studies have demonstrated safe administration of local anaesthetic and adrenaline (LAA) in hand procedures including digital blocks. The use of LAA removes the need for a tourniquet, improving tolerability. Although there is UK evidence supporting this technique in carpal tunnel release (CTR), there is less in relation to other procedures. We have recently increased our LAA procedure repertoire. We demonstrate by prospective audit patient satisfaction as well as other improvements.

Methods: Between August and December 2011 we provided a questionnaire for all patients attending Royal Bolton Hospital for upper limb surgery performed under LAA. We used bupivacaine 0.25–0.5% and adrenaline (1 in 200,000).

Results: There were forty-eight procedures on 47 patients. The procedures performed included CTR, excision of ganglion and cyst, trigger finger release, fasciectomy, DIP joint fusion, tennis elbow release, repair of ligament and tendon, EUA and excision biopsy. 72% of patients described the process as “As pleasant as could possibly be expected” and 28% described it as “Not bad”. All

patients claimed they would like similar procedures performed under LAA in future. Of those who had had previous similar surgery under general anaesthetic, 100% preferred our method. We performed up to eight LAA procedures in a half day list.

Conclusion: Our results demonstrate that patients appreciate the technique. We did not require an anaesthetist, ODP or recovery staff. We did not use an arm tourniquet. We advocate this as comfortable, efficient and safe method preferred by patients.

30 Simplifying the method of assessing volar alignment of distal radial fractures: investigating radio-lunate relations using MRI

Mr J Wohlgemut, Mr G Medlock, Mr I Stevenson, Professor A Johnstone (Aberdeen)

Introduction and Aims: Treatment of distal radial fractures (DRF) aims to restore anatomical alignment. Standard lateral radiographs can be difficult to interpret in the presence of even slight malrotation. We have identified new anatomical landmarks that ease assessment of DRF reduction on lateral radiographs: the relationship between the dorsal radial cortex (DC) and superior pole of the lunate (SL). We aim for MRI validation of this novel method of assessing DRF reduction using the hypothesised constant relationship between the DC and the SL.

Materials and Methods: MRI scans of twenty-eight normal wrists were examined. Scans included the distal third of the radius to the proximal carpal row. Beginning 5cm proximal to the distal radius articular surface, a line was superimposed upon the DC extending distally through the metaphyseal flare. Lunate height (LH) and distance from the DC line to the SL (DC-SL) were measured at 5° rotational increments around the radial shaft central axis to a total of 30° of supination and pronation (S+P). The DC-SL/LH ratio was compared to 0° (anatomical lateral) using the two-tailed paired Student t-test.

Results and Statistics: There was no significant difference in DC-SL/LH between 0° of rotation and any 5° increment up to 30° of S+P (lowest p=0.075). The DC line lay consistently dorsal to the SL.

Conclusions and Clinical Reference: A constant DC-SL relationship exists with up to 30° of S+P. This technique can easily be used to quickly and accurately assess DRF reduction in poorly-taken films with malrotation up to 30° from anatomical lateral.

31 An anti-adhesive with antibacterial properties - A critical appraisal of its first clinical application in hand surgery

Dr T Doehnicke, Mr O Bach, Mr R Friedel, Professor G Hofmann (Jena)

Introduction and Aims: Several substances have been tried with no success for the prevention of adhesion formation around tendons and nerves. One major concern is a possible permissive effect on infection by acting as a foreign body. Collagen foil has been shown to prevent adhesions for instance intra-abdominally. If it would be impregnated with Gentamycin, infection hazards would be minimal. Moreover, it could act as a carrier for local antibiotic useable within the anatomically confined spaces of the hand where there is no room for collagen sponges or PMMA mini bead chains.

Material and Methods: Gentamycin impregnated equinous collagen foil (GENTA-COLL resorb Foil®) has been in clinical use at a major hand surgical referral and replantation centre since March 2007. Indications, mode of application, intra-operative handling and clinical outcome have been recorded prospectively for the first forty consecutive cases.

Results: In thirty-three cases tendons have been covered to avoid adhesions following tendon repair their recurrence after tenolysis. In three other cases major peripheral nerves were coated after microsurgical repair. No wound infection transpired. Twice excessive wound discharge was noted but settled without intervention, while in one other case after excessive application of the material a fistula developed that required surgical revision. Two tendon ruptures occurred, both

after extensive flexor tenolysis. In four cases the substance was solely used as local antibiotic to treat infection with clinical success.

Conclusions: Genatmycin impregnated collagen foil warrants cautious use in intricate clinical scenarios and further research. Its functional benefit as an anti-adhesive has to be demonstrated yet.

32 Severity of upper limb panga injuries and infection rates in early versus late tendon repair

Mr N Howard, Mr P Rollinson (Kwazulu-Natal)

Panga or machete attacks are common causes of significant upper limb trauma in South Africa. Almost all are due to interpersonal violence. Pangas are a multipurpose household tool used predominantly for foraging and agricultural purposes and are highly contaminated. With injuries involving damage to important structures, concern exists about immediate repair due to the risk of significant infection. Whilst some centres advocate immediate primary repair, other centres delay repair until satisfied there is no evidence of infection.

We conducted a multi centre retrospective observational study comparing infection rate and tendon re-rupture following early primary repair (less than 24hrs), primary repair after 24hrs vs delayed repair following initial debridement. Forty-nine patients (mean age 28.9, 17 - 69) were recruited into the study and followed up for a mean of 3.4 months (range 0 - 8 months). Included in the forty-six patients there were 32 flexor tendon injuries, 14 extensor tendon injuries, 9 fractures and 21 peripheral nerve injuries.

Seventeen were repaired primarily early (<24 hrs), 19 had delayed primary repair and 13 had a delayed repair following primary washout. Post-operatively wounds were assessed using the Asepsis wound scoring system and patients clinically assessed for tendon re-rupture. No significant difference was found ($p=0.662$) in the comparative infection rates of early versus late 6.2% (+/- 7.7 CI 95%) v 18.1% (+/- 22.8 CI 95%) or rupture rate (5.7% v 9%).

Our results would indicate that panga injuries can be safely repaired at first presentation

33 Gouty Flexor Tenosynovitis: When to operate?

Miss M Mughal, Mr F Henry, Miss B Jemec (London)

Introduction: Flexor tenosynovitis is an unusual manifestation of gout. The clinical presentation often mimics infection thus masking the true diagnosis.

Material: We discuss two cases of gouty flexor tenosynovitis that were initially misdiagnosed as infection and treated with different modalities.

Case 1: A 55-year-old male was referred by orthopedics after washout of a presumed carpal tunnel infection two weeks post CTD. He presented with a three-day history of erythema and pain over his right little finger. An ultrasound scan confirmed flexor tenosynovitis with fluid in the flexor sheath. His inflammatory markers were normal. He then underwent surgical exploration, which showed soft tissue deposits along flexor digitorum profundus but no pus. Post-op urate levels were 0.47mmol/L.

Case 2: A 53-year-old previously healthy male with two-week history of a painful, erythematous right middle finger was admitted for elevation and IV antibiotics. Inflammatory markers were mildly raised but WBC was normal. The U/S scan reported by the MSK radiologist showed a flexor tenosynovitis due to calcific deposits suggestive of gout along the flexor tendon but no fluid. His serum urate levels were 0.58mmol/L and he was commenced on Colchicine. NSAIDS were prescribed on discharge with resolution of symptoms.

Conclusion: Gouty flexor tenosynovitis can present as a diagnostic dilemma. Modern ultrasonography performed by musculoskeletal radiologists can help avoid unnecessary surgical interven-

tion. We advocate that careful clinical assessment and radiological evaluation in management of these cases can prevent surgical morbidity and also prove to be cost effective.

34 Current practice in tennis elbow management: A survey of specialist opinion and practice

Mr A Titchener, Mr A Tambe, Mr D Clark (Derby)

Introduction: Tennis elbow is a common condition and has frequently been managed using corticosteroid injection. Recent evidence has suggested this is effective in the short term, but over longer periods their effects may be deleterious. We have undertaken a nationwide survey of upper limb specialists to assess current practice.

Method: Internet based survey software was used to issue a multiple choice based online questionnaire via email to members of the British Society for Surgery of the Hand and the British Elbow and Shoulder Society.

Results: 269 responses were received. Consultant surgeons comprised the largest group (231/269, 85.9%). 130 members (48.3%) use corticosteroid injections as their first line treatment for tennis elbow, with 138 (51.3%) using this for the majority of their patients. 206 respondents (76.6%) believe that corticosteroid injections are not potentially harmful in the treatment of tennis elbow while 39 (14.5%) do not use them in their current practice. In light of recent evidence 135 respondents (50.2%) have not changed their practice with regards to the use of corticosteroids, while 108 (40.1%) have reduced or discontinued their use. 43 respondents (16.0%) have used platelet rich plasma injections with 49.3% believing they were effective. 170 respondents (63.2%) routinely use a counterforce brace as part of their management.

Conclusions: There has been a recent expansion of evidence addressing the non-operative management of tennis elbow. This appears to have had a limited effect on current practice; a large group are still using corticosteroids. Our study reveals an interesting picture, including an increasing trend in the use of platelet rich plasma injections.

35 The accuracy of direct magnetic resonance arthrograms (MRA) in detecting triangular fibrocartilage complex (TFCC) and inter-carpal ligament tears

Mr S Sawalha, Ms R Ravikumar, Mr A McKee, Mr G Pathak, Mr J Jones (Peterborough)

Introduction: Direct MRA has been reported in some studies to be a highly sensitive and specific diagnostic tool that can replace wrist arthroscopy. Other studies found that wrist MRA does not reliably rule out TFCC tears. This study reports the accuracy of direct MRA in detecting TFCC, scapho-lunate ligament (SLL) and luno-triquetral ligament (LTL) tears using wrist arthroscopy as the gold standard.

Methods: We reviewed the records of all patients who underwent direct wrist MRA and subsequent arthroscopy between June 2007 and March 2011. Demographic details, MRA findings, arthroscopy findings and the time interval between MRA and arthroscopy were recorded. Sensitivity, specificity, positive and negative predictive values (PPV & NPV) were calculated using arthroscopy as the gold standard.

Results: Two hundred and thirty four (234) MRA were performed over the study period. Fifty patients (50) who underwent 51 wrist arthroscopies (one bilateral) were included. The mean age was thirty-five years (range 16–64 years). The average delay between MRA and arthroscopy was 4.8 months (median 4 months, range 17 days - 18 months). At arthroscopy, 26 TFCC tears, 7 SLL tears and 3 LTL tears were found.

	Sensitivity (%)	Specificity (%)	PPV (%)	NPV (%)
TFCC	96	88	89	96
SLL	57	66	21	91
LTL	67	79	17	97

Conclusion: MRA is a sensitive and specific imaging modality for diagnosing TFCC tears. However, the diagnostic accuracy for SLL and LTL tears was not satisfactory. Wrist arthroscopy remains the gold standard if there is a clinical suspicion of inter-carpal ligament pathology.

36 Symptomatic extra-articular scaphoid tuberosity non-union - Two cases of successful surgical excision of the un-united fragment after failed conservative management
Ms N Muirhead ,Dr L Garagnani (London)

Purpose: Management of symptomatic non-union of the scaphoid tuberosity is a rare clinical dilemma which does not appear to fall into the Herbert classification. This study assesses the outcomes and describes the technique of surgical excision of the un-united fragment in two cases of symptomatic scaphoid tuberosity non-union after failed non-operative management in young and healthy individuals.

Methods: Two male patients presented to our hand unit with long-standing symptoms from un-united extra-articular scaphoid tuberosity fractures, following failed non-operative management. Mean age at presentation was twenty-three (range 22-24 years). The patients were assessed clinically and radiographically. A CT scan was obtained in both cases to assess size, shape and position of the un-united fragment. Surgical excision of the un-united bony fragment was carried out. Total post-operative follow-up was six months. Pre-operative and post-operative pain scores on the Numerical Rating Scale (NRS) were obtained. The QuickDASH questionnaire was administered pre-operatively and at six months follow-up.

Results: Pain scores on the Numerical Rating Scale (NRS) were reduced from pre-operative scores of 6/10 and 7/10 to short-term post-operative scores of 0/10 and 2/10 respectively, at five days follow-up. At six weeks follow-up, both patients had already returned to work. QuickDASH scores confirmed significant improvement of symptoms and function in both patients.

Conclusion: We describe a sub-group of scaphoid tuberosity fractures that remain un-united and symptomatic. Our experience suggests that surgical excision of the un-united fragment is a viable option for management of symptomatic extra-articular fractures of the scaphoid tuberosity after failure of non-operative management.

37 Non-scaphoid carpal injuries - Incidence and associated injuries
Mr A K Raghupathi, Mr M Mawdsley, Mr K Prathap Kumar (London)

Introduction: Scaphoid fractures constitute 62-87% and non-scaphoid fractures comprise approximately 40% of all carpal fractures[2]. Non-scaphoid carpal fractures and associated injuries are frequently missed and difficult to diagnose and late diagnosis can lead to serious ligamentous disruption and permanent wrist dysfunction[1].

Aims: To identify the incidence of non-scaphoid carpal fractures in our population, comparing it with literature and to analyse the patterns of associated injuries.

Methods: A retrospective analysis of all wrist X-rays and CT scans was carried out in our hospital for a three-year period from 2008 to 2011. A total of thirty-three patients were included in our study. Case notes were accessed to gather clinic data. Incidence and associated injuries from this study were compared with the literature.

Results: There is an increased association of scaphoid fractures (n=3 each) with triquetral and hamate fractures.

Carpal fractures excluding scaphoid	Number (in our study)
Triquetrum	13
Hamate	10
Capitate	5
Lunate	4
Trapezium	3
Pisiform	2
Trapezoid	0

Incidence:

Fracture	Our study	Literature
Triquetrum	35%	4–31%
Hamate	27%	7%
Capitate	14%	1.3%
Lunate	11%	1%
Trapezium	8%	3–5%
Pisiform	5%	1–2%

Conclusion: The incidence of non-scaphoid carpal fractures in our study is considerably higher when compared to the literature. We would stress the importance of always looking for any associated injuries with any type of carpal fractures based on our study findings. We propose that a high index of suspicion should always be borne in mind when dealing with carpal fractures and detailed examination of the wrist should be conducted, even when X-rays do not show any obvious bony injuries, if persistent symptoms are present. CT scans and other specialised images should be judiciously used in areas of suspicion for early diagnosis, to initiate adequate and immediate treatment, for early mobilisation and good functional recovery.

References:

1. Vigler M, Aviles A, Lee SK. Carpal fractures excluding the scaphoid. *Hand Clin* 2006; 22: 501–516.
2. Hove LM. Fractures of the hand: Distribution and relative incidence. *Scand J Plast Reconstr Surg Hand Surg* 1993; 27: 317–319.

38 Open inferior arc injury: Case series and outcome

Mr S J Rhee, Mr C Ramamurthy, Mr D Morley, Mr N Neal, Mr K Smith (Stoke on Trent)

Introduction: Complex wrist injuries are typically classified according to the standard “greater arc” and “lesser arc”. More recently, however, the spectrum of transverse instability of the wrist has been extended to involve the “inferior arc”, a term introduced by Graham TJ (2003). Such traumatic injuries, although rare, involve high velocity and the extent of injury is often misjudged, leading to under-treatment with poor results.

Aim: We present a series of open inferior arc injuries and their post-operative outcomes, to our knowledge a first of its kind.

Materials and Results: Between 2008–2011, we treated four cases of inferior arc injuries which were open (Grade II and less). Three cases underwent initial external fixation, with secondary internal fixation with distal radial plates. Functional outcomes were poor with corresponding poor MAYO clinical wrist scores. Case 4 had primary anatomical internal fixation, with cannulated screw fixation of the radial and ulna styloid. At twelve weeks, the wrist was stable with return to normal activity, and the MAYO clinical wrist score was 75.

Conclusion: Our case series, along with other reports, highlights the rarity of such injuries. Inferior arc injuries are complex injuries to manage, and the outcome of surgical intervention yields poor outcome. We have highlighted that open injuries should be managed according to basic

trauma principles, however, it is vital to understand the nature of force transmission, and respect the soft tissue component to the injury. We feel that primary anatomical reduction of the bony fragments with early mobilisation will enhance functional outcome.

39 Is the scaphoid trapezium pyrocarbon implant the solution to scaphotrapeziotrapezoid osteoarthritis? A multi-centre case series

Miss M C Nogaró, Mr H Budd, Mr T Harrison, Mr J Stanton, Mr J Jones (Peterborough)

Aim: Interposition of a pyrocarbon prosthesis is a novel technique in managing scaphotrapeziotrapezoid joint (STTJ) osteoarthritis, with sparse outcome data available in the literature. This study aimed to determine the functional and radiological outcome of scaphoid trapezium pyrocarbon implant (STPI) insertion, following failure of conservative treatment for STT joint osteoarthritis, while clarifying the complication rate.

Methods: This is a retrospective case series of twelve patients receiving an STPI prosthesis for isolated STTJ osteoarthritis by consultant hand surgeons in three UK hand units. We used the QuickDASH questionnaire and Patient Rated Wrist/Hand Evaluation to assess patient-reported outcomes in addition to radiographic follow-up and functional assessment by a hand therapist.

Results: Eight patients were female, and the mean age was 60 years (50 to 77). The mean follow-up time was 3.1 years. Hand strength was greatest on the operative side in most patients, with range of motion mildly reduced in the operative hand. There were no cases of implant fracture, however one radiograph demonstrated implant subluxation and 2 showed evidence of surrounding osteolysis. Patients were generally satisfied with their hand function at follow-up with a mean QuickDASH score of 14 and most patients returning to their previous occupation within a year.

Conclusion: This is the first STPI case series reported in the UK and demonstrates a lower complication rate, specifically dislocation, than previous studies. While this is a small study, the results at over three years follow-up are satisfactory and may be attributable to the unique biomechanical properties of this implant.

40 Role of MRI in the diagnosis of traumatic wrist pain

Mr A Mustafa, Mr M Al-Najjim, Mr S Rhee, Mr S Morapudi, Mr M Waseem (Macclesfield)

Objectives: To evaluate the role of MRI in the early diagnosis of acute wrist pain not diagnosed by the conventional imaging following recent trauma.

Methods: Consecutive data was collected retrospectively between January 2007 to December 2008 for patients who had MRI scans for acute wrist pain following recent trauma. All patients who had MRI scans for traumatic wrist pain due to unconfirmed diagnosis were included in the study. Patients with chronic wrist pain and who had no history of trauma were excluded from the study.

Results: 126 patients were identified. There were 76 male and 50 female patients. The mean age was 39.5 years (10–79), mean time for the scan was 12.5 days (0–32). Positive MRI finding in 60 (47.6%) patients. 39 patients had different bone pathologies, which included 14 scaphoid fractures, 13 carpal fractures other than scaphoid, 8 distal radius fractures, 3 metacarpal fractures and 1 scaphoid cyst. 21 patients had soft tissue injuries, which included 8 triangular fibrocartilage complex (TFCC) injuries, 6 scapho-lunate disruption, 5 tenosynovitis and 2 ganglion.

Conclusion: This study demonstrates that patients with painful wrist can have a wide range of diagnoses. Inaccurate diagnosis has social and financial implications. MRI plays a superior role in the diagnosis of wrist pathology and has 100% sensitivity and specificity in the diagnosis of scaphoid fractures. It helps in early accurate diagnosis and is also able to pick up associated injury or pathology. It does not require any special positioning of painful wrist and there is no exposure to ionising radiation.

41 Surgical options in managing failed trapeziectomies: A series of four cases
Mr A Manohar, Mr C Ng, Mr S Talwalkar, Mr M J Hayton (Wigan)

Introduction: Trapeziectomy is an effective treatment of thumb carpometacarpal arthritis. However some patients may subsequently develop proximal migration of the metacarpal leading to pain and loss of function. We report our experience of managing failed trapeziectomy.

Methods: We identified four patients who developed painful subsidence of the metacarpal following trapeziectomies from the database. Three patients were treated with fusion of the bases of the first and second metacarpals, using K-wires or compression screws. Another patient underwent a mini tight rope suspension reconstruction.

Results: Average age of the patient was fifty-seven years (43-65). Average period following trapeziectomy was six years (4-10). The average duration of follow-up was twenty-eight (8-60) months. Three of the 4 patients were seen to have satisfactory clinical and functional outcomes. One of the patients who underwent fusion developed hypertrophic non-union and a revision fusion was performed.

Conclusion: Failed trapeziectomy remains a challenging problem. Fusion of the bases of the first and second metacarpals and mini tight rope suspension reconstruction are two options for salvage procedures.

42 A journey to wrist joint arthroscopy: Accuracy of clinical examination and MRI
Mr R Bawale, Mr B Singh (London)

Introduction: The wrist arthroscopy has been performed since 1979. Wrist arthroscopy has become a gold standard for diagnosing TFCC pathologies and other intercarpal disorders.

Aim: Our aim was to compare the clinical, MRI and arthroscopic findings while treating various wrist pathologies.

Methods: In this study, we reviewed forty-one patients treated by the senior surgeon between March 2009 and November 2011. Inclusion criteria: TFCC, S-L, LTL injuries and articular cartilage damage, synovitis. Exclusion criteria: septic arthritis, acute distal radius fractures. Kappa analysis was used to compare the three methods of wrist pathology assessment.

Results:

Table 1:

	Clinical Findings	MRI report	Arthroscopic findings
TFCC tear	30	28	26
S-L tear	13	9	13
Cartilage damage	12	18	19
Synovitis	15	22	26

Table 2:

	Clinical Findings	Arthroscopic findings	Clinical examination	Sensitivity specificity
TFCC tear	30	26	93%	90%
S-L tear	13	13	99%	99%
Cartilage damage	12	19	70%	68%
Synovitis	15	26	60%	55%

Table 3:

	MRI	Arthroscopic findings	MRI	Sensitivity specificity
TFCC tear	28	26	95%	92%
S-L tear	9	13	75%	70%
Cartilage damage	18	19	96%	94%
Synovitis	22	26	88%	84%

Clinical examination had poor correlation with wrist arthroscopy in diagnosing synovitis.

Conclusions: Clinical examination and MRI has good sensitivity and specificity for TFCC tears. MRI is good at synovitis and cartilage damage, but S-L is better judged clinically. Our results showed clinical examination is crucial, MRI is used as an adjunct but the wrist arthroscopy remains the gold standard tool for diagnosis and therapeutic interventions.

References:

1. Rose S, Frank J, Marzi I. Diagnostic and therapeutic value of wrist arthroscopy in the treatment of distal radius fracture. *Zentralbl Chir* 1999; **124**: 984–992.
2. Gupta R, Bozentka DJ, Osterman AL. Wrist arthroscopy: The principles and clinical applications. *J Am Acad Orthop Surg* 2001; **9**: 200–209.
3. Mutimer J, Green J, Field J. Comparison of MRI and wrist arthroscopy for assessment for wrist cartilage. *J Hand Surg Eur Vol* 2008; **33**: 380–382.

43 **Scaphoid fractures in the elderly**

Dr E Rudge, Miss R Farrimond, Mr A Kocheta (Rotherham)

Introduction: The scaphoid bone is the most commonly fractured carpal bone, accounting for approximately 70% of all carpal bone fractures. The infrequency with which it is encountered in the elderly, however, makes it a diagnostic challenge.

Case Presentations: A 74-year-old lady presented after falling backwards on to an outstretched left hand. Examination revealed swelling and bruising, with tenderness over the dorsum of the hand. No tenderness was elicited over the scapholunate joint, anatomical snuffbox, distal pole of the scaphoid or on compression of the thumb. Imaging revealed a line through the scaphoid, with evidence of pre-existing scaphotrapezotrapezoidal (STT) joint arthritis. She was admitted for reduction of swelling and a conservative management plan was adopted, with the wrist immobilised in a below elbow, neutral cast. A good outcome was achieved.

An 86-year-old lady also presented following a fall backwards on to an outstretched left hand. Examination revealed swelling and bruising to her left wrist with significant tenderness over the anatomical snuffbox. Imaging identified a scaphoid fracture, again with evidence of STT arthritis. She was immobilised in a below elbow scaphoid backslab for six weeks. Routine follow-up demonstrated that the patient had good wrist function and no residual tenderness.

Discussion: These cases challenge epidemiological studies, which tend to demonstrate a predominance of scaphoid fractures in the young and, more often, male population. This report aims to encourage consideration of scaphoid fracture as a differential diagnosis in the elderly to minimise mis-diagnosis and, therefore, reduce poor functional outcome in this population.

BSSH AUDIT DATABASE

OFFICIAL LAUNCH: SPRING SCIENTIFIC MEETING, MAY 2012

Surgeons are increasingly obliged to audit their results and it will soon be mandatory to provide evidence of achieving satisfactory surgical outcomes in order to revalidate. Collecting, collating and analysing surgical outcomes can be labour intensive and the process is rarely adequately resourced. Unless matched data from other surgeons is available for comparison, the results may not be meaningful.

The British Society for Surgery of the Hand has recognised the importance of surgical audit and the practical difficulties associated with achieving it. For the benefit of its members, BSSH has developed a web-based hand surgery audit tool and is employing a full-time Database Administrator to undertake the vast majority of the data collection and entry. This resource is available, free of charge, to all BSSH members.

The audit tool will allow surgeons to audit their outcomes with minimal effort and compare their own results with those of the BSSH dataset. Surgeons are encouraged to use their outcome data to inform their own appraisal and continuing professional development.

HOW IT WORKS

The available audits, score systems and follow-up time-points are defined by the website. Surgeons may enter one or many audits for whatever length of time they select. It is envisaged that most surgeons will audit a procedure for a year or two, check their outcomes are satisfactory and then move on to audit a different procedure.

For any patient having a surgical procedure that is being audited, the surgeon must enter the patient's ID details and the date and type of operation on the website. The patient is asked pre-operatively to complete the designated self-administered scores, which are sent to the BSSH offices. The surgeon need do nothing more.

The BSSH Database Administrator will enter the patient's pre-operative scores onto the database and arrange subsequent outcome scoring of the patient at the defined post-operative follow-up time-points. The patient's outcome data will accumulate on the website over time. The surgeon is able to track the scores and use the website tools to analyse the data and make comparisons against the website's full dataset.

SECURITY

The site is accessible by BSSH members only. Individual surgeons' data is not available to BSSH members outside their own hospital and is held centrally in encrypted form. The website is approved for data protection by the National Information Governance Board.

GETTING STARTED

BSSH members will receive a username and password for the audit database by email. The site can be accessed at <https://bssh.nuvola.co.uk> or via the main BSSH website www.bssh.ac.uk.

- Enter the website, log in and change your password to one of your own choosing if you wish.
- Go to: Audits – Current Procedure Types, and see what is available for auditing. Note the score systems that will be used in each audit and the follow-up time-points.
- Decide which procedure you wish to audit, over what time frame. Go to: Procedures I'm Auditing and enter your audit dates (for example, you may wish to audit trapeziectomies over a twelve-month period starting from now, in which case you would enter today's date and a year hence as the end date. Note that the follow-up data would continue to be collected until the final follow-up time-point, twelve months after you finish entering patients into the audit).
- When you have a patient attending for surgery that you wish to enter into your audit, you need to do the following:
 - 1) Go to: Patients – New Patient and enter the patient's ID details. You need date of birth, sex, and either the patient's hospital number or their NHS number. Note that the patient is allocated an anonymous database ID number – only this will be visible centrally and is the number by which the Database Administrator will identify the patient.
 - 2) Go to: Enter New Procedure for Patient and enter what type of operation is being done and the date of surgery.
 - 3) Check which scoring systems are being used for that procedure type (listed under: Audits – Current Procedure Types). Go to: Audits – Score Set Info – Print and print off the required score sheets (for trapeziectomy, the score systems used will be the Patient Evaluation Measure and the EQ5D). Write the patient's database ID number on the score sheets (by BSSH Ref: PA) and hand them to the patient to self-complete. Once completed, the score sheets need to be send to:
BSSH Database Administrator, British Society for Surgery of the Hand
The Royal College of Surgeons of England, 35–43 Lincoln's Inn Fields, London WC2A 3PE.
- Surgeons may find it helpful to have a folder in their briefcase containing score sheets and stamped addressed envelopes to the BSSH, so they can hand them to patients to complete and mail on the morning of their surgery.
- The surgeon need do nothing more...
- The BSSH Database Administrator will enter the patient's pre-operative scores and arrange outcome scoring of the patient at the defined post-operative follow-up time-points. The patient's outcome data builds up on the website and the surgeon is able to use the website tools to analyse the data and make comparisons against the website's full dataset.

MEETING INFORMATION

REGISTRATION

REGISTRATION

Important notice: Doctors or scientists engaged in research AND presenting a paper will not be charged a registration fee for the day they are presenting, if they can confirm in writing that they have no access to study leave expenses. They must, however, pay £40 per day. This is the day delegate rate charged to the Society by the venue for each individual attending.

Exemption from payment of registration fees is not available to those who have access to study leave. If all study leave for the year has been utilised, full registration fees must be paid.

REGISTRATION FEES

Full / Overseas / Associate Members who are Consultants	£280 Whole meeting £140 One day
Associates who are Trainees / Companion Members / Non-members UK Trainees	£155 Whole meeting £80 One day
Other Non-members	£280 Whole meeting £140 One day
Honorary / Senior Members	£40 per day
Speakers who are Research Doctors or Scientists	£40 per day

On-site registrations do not include a ticket to the Society Dinner.

REGISTRATION AND ENQUIRY DESK

The Registration and Enquiry Desk (situated in the Foyer on the ground floor of the Royal College of Surgeons) will be open at the following times:

Thursday 09:00 – 17:30

Friday 08:00 – 16:00

The telephone number of the Registration and Enquiry Desk during the meeting is: 07930 509 646 (BSSH Mobile).

HONORARY AND SENIOR MEMBERS

Honorary and Senior Members will not pay a registration fee. A charge of £40 will be made for refreshments and luncheon each day. This is the day delegate rate charged to us by the venue for each delegate.

MEETING INFORMATION

VENUE

VENUE OF THE SCIENTIFIC MEETING

The meeting will be held in Lecture Room 1 at the Royal College of Surgeons.

CONGESTION CHARGE

The Royal College of Surgeons is within the charging area.

CAR PARKING

There is no car parking at the Royal College of Surgeons. There is an NCP on Kemble Street, off Kingsway.

ACCOMMODATION

No block bookings have been made for the meeting. Delegates should book their accommodation with the hotel directly.

Renaissance London Chancery Court Hotel

252 High Holborn, London WC1V 7EN, Tel: 020 7829 9888

Website: www.marriott.co.uk/hotels/travel/loncc-renaissance-chancery-court-london/

Grange Holborn Hotel

50-60 Southampton Row, London WC1B 4AR, Tel: 020 7242 1800, Website: www.grangehotels.com

Strand Palace Hotel

372 Strand, London WC2R 0JJ, Reservations: 020 7379 4737, Website: www.strandpalacehotel.co.uk

TravelLodge Covent Garden

10 Drury Lane, High Holborn, London WC2B 5RE, Tel: 0871 984 6245,

Website: www.travellodge.co.uk

Premier Inn Kings Cross

26-30 York Way, Kings Cross, London N1 9AA, Tel: 0871 527 8672, Website: www.premierinn.com

Hotel Booking Websites

www.activehotels.com

www.hoteldirect.co.uk

www.laterooms.com

LUNCHEON

Luncheon will be served in the Edward Lumley Hall.

MEETING INFORMATION

MISCELLANEOUS

CONTRIBUTORS INFORMATION

There will be projection facilities for PowerPoint presentations only.

Speakers are asked to keep strictly to the time allocated for their presentation.

CONTINUING MEDICAL EDUCATION

The following number of points have been awarded for each day:

Thursday:	6.0
Friday:	6.5
Total:	12.5

SOCIETY DINNER

Thursday, 3 May at 19:30 for 20:00

The Royal College of Surgeons, Edward Lumley Hall

Dress code: dark lounge suit

The Society Dinner is open to Honorary, Senior and Full Members and Associates, all of whom may invite guests. One ticket was included in the registration fee for those who pre-registered for the whole meeting.

PRIZES

A prize consisting of book vouchers to the value of £250 will be awarded to the best e-Poster presented at the meeting.

KEYNOTE LECTURES

Thursday	14:00	My experience treating sportsmen in the USA by Dr M E Baratz
Thursday	16:30	Commissioning in the hand by Professor J J Dias
Thursday	17:00	Tackling mountains of adversity by Mr J Andrew
Friday	13:30	What's new in Kienböck's? by Professor L de Smet

MEETINGS

BSSH Business Meeting

The BSSH Business Meeting will be held on Thursday, 3 May at 17:30 in Lecture Theatre 1 (open to Members and Associates only).

Meetings in 2012

11–12 October: Royal York Hotel, York

Meetings in 2013

25–26 April: International Centre, Harrogate

17–18 October: Royal College of Surgeons, London (combined meeting with BAHT)

MEDICAL AND TECHNICAL EXHIBITION

Firms supplying instruments, appliances, materials and books will be exhibiting throughout the two days in the Edward Lumley Hall, where refreshments and luncheon will be served. It is hoped that everyone will support this exhibition.

TRADE EXHIBITORS

ADVANTECH SURGICAL LTD 7 The White House, 42/44 The Terrace, Torquay, Devon TQ1 1DE Telephone: 0845 130 5866, Fax: 0845 130 5866, Email: mail@advantechsurgical.com Contact: Mr S Knoble	STAND NO 12
ARTHREX LTD Unit 5, 3 Smithy Wood Drive, Smithy Wood Business Park, Sheffield S35 1QN Telephone: 0114 232 9180, Fax: 0114 257 8929, Email: roselyn.barber@arthrex.co.uk Contact: Mrs R Barber	STAND NO 13
B BRAUN MEDICAL Thornclyff Park, Sheffield S35 2PW Telephone: 0114 225 9000, Email: phil.cleary@bbraun.com Contact: Mr P Cleary	STAND NO 9
BSSH RESEARCH AND AUDIT COMMITTEE British Society for Surgery of the Hand, Royal College of Surgeons, 35-43 Lincoln's Inn Fields, London WC2A 3PE Telephone: 020 7831 5162, Fax: 020 7831 4041, Email: research@bssh.ac.uk Contact: Miss S Fullilove	STAND NO 15
CLS SURGICAL LTD Coach House, The Green, Wallsend, Tyne and Wear NE28 7PG Telephone: 07768 271 791, Fax: 0191 213 5953, Email: chris@cls-surgical.com Contact: Mr C Bond	STAND NO 14
MEDARTIS Suite 63, Annexe 4, Batley Business Park, Technology Drive, Batley, West Yorkshire WF17 6ER Telephone: 0192 447 6699, Fax: 0192 447 2000, Email: nadia.gershkovich@medartis.com Contact: Ms N Gershkovich	STAND NO 10
MEDIRACER UK LTD Technology Centre, Wolverhampton Science Park, Wolverhampton WV10 9RU Telephone: 0844 800 2617, Fax: 0844 800 2618, Email: info@mediracer.co.uk Contact: Mr N Hamar	STAND NO 8
NORMED MEDIZIN-TECHNIK GMBH Ulrichstrasse 7, 78532 Tuttlingen, Germany Telephone: 00 49 7461 934 319, Fax: 00 49 7461 934 420, Email: j.stellmacher@normed-online.com Contact: Mr J Stellmacher	STAND NO 5
NORTHSTAR ORTHOPAEDICS LTD Northstar House, 26 Kingfisher Court, Hambridge Road, Newbury, Berkshire RG14 5SJ Telephone: 01635 275 380, Fax: 01635 275 381, Email: sacha@northstar-ortho.co.uk Contact: Ms S Bartlett	STAND NO 2
OSTEOTEC LTD 9 Silver Business Park, Airfield Way, Christchurch BH23 3TA Telephone: 01202 487 885, Fax: 01202 487 886, Email: susann@osteotec.co.uk Contact: Ms S Idres	STAND NO 6
POLYGANICS Rozenburglaan 15A, 9727 DL Groningen, The Netherlands Telephone: 00 31 50 5886 588, Fax: 00 31 50 5886 599, Email: d.mccurdy@polyganics.com Contact: Mr D McCurdy	STAND NO 7
PRIMAL PICTURES LTD 4th Floor, Tennyson House, 159-165 Great Portland Street, London W1W 5PA Telephone: 020 7636 1010, Fax: 020 7636 7776, Email: dan@primalpictures.com Contact: Mr D McGarry	STAND NO 16

TRADE EXHIBITORS

SAGE PUBLICATIONS LTD

1 Oliver's Yard, 55 City Road, London EC1Y 1SP

Telephone: 020 7324 8608, Fax: 020 7324 8700, Email: Catherine.layton@sagepub.co.uk

Contact: Ms C Layton

STAND NO 1

STRYKER MEMOMETAL

Hambridge Road, Newbury RG14 5EG

Telephone: 01635 262400, Fax: 01635 580 300, Email: ian.hughes@stryker.com

Contact: Mr I Hughes

STAND NO 11

SOVEREIGN MEDICAL LTD

Unit 16, M11 Business Link, Parsonage Lane, Stansted, Essex CM24 8GF

Telephone: 01279 816 167, Fax: 01279 816 299, Email: Natalie@sovereignmedical.co.uk

Contact: Mr R Kinzer

STAND NO 3

VERTEC SCIENTIFIC

Unit 44, Easter Park, Benyon Road, Silchester, Reading RG7 2PQ

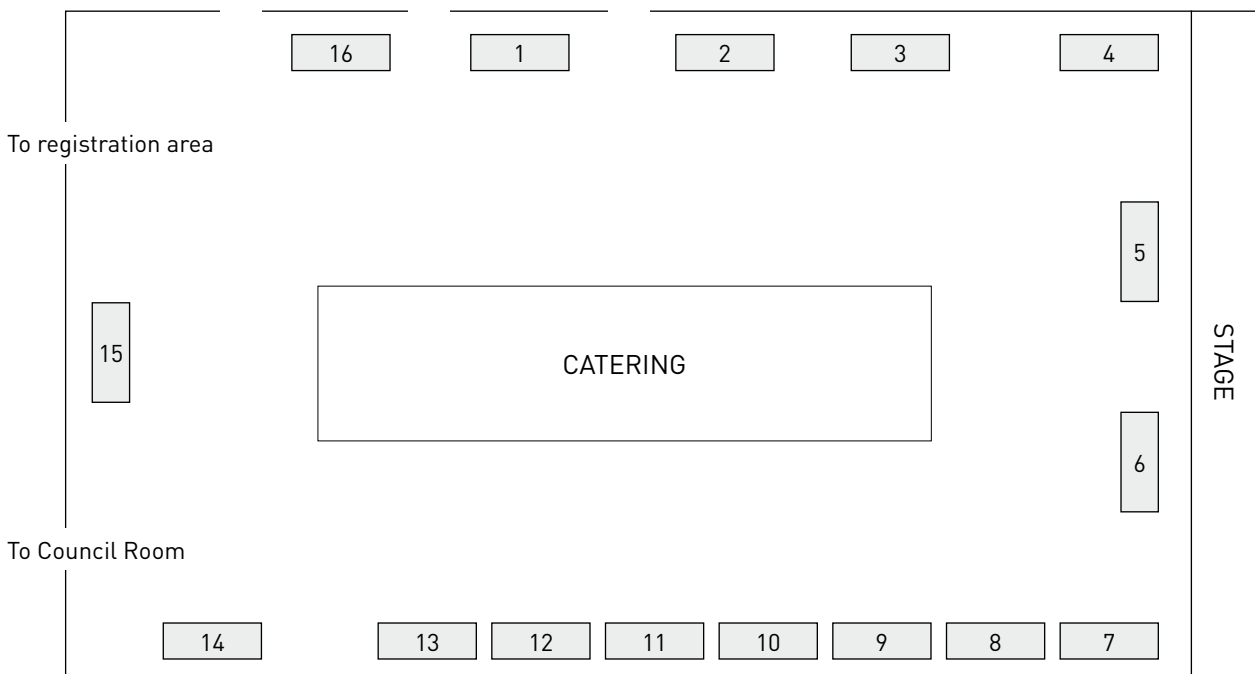
Telephone: 01189 702 104, Fax: 01189 701 861, Email: nviccars@vertec.co.uk

Contact: Mr K Lakin

STAND NO 4

FLOOR PLAN

EDWARD LUMLEY HALL





BSSH

at the Royal College of Surgeons
35-43 Lincoln's Inn Fields
London WC2A 3PE

The British Society for
Surgery of the Hand

Tel: 020 7831 5162
Fax: 020 7831 4041
Email: secretariat@bssh.ac.uk

