

BSSH

The British Society for
Surgery of the Hand

SCIENTIFIC MEETING

31st March - 1st April 2011

THE LOWRY ART & ENTERTAINMENT CENTRE
SALFORD QUAYS
MANCHESTER

PROGRAMME



BRITISH SOCIETY FOR SURGERY OF THE HAND

at the Royal College of Surgeons
35-43 Lincoln's Inn Fields, London WC2A 3PE
Tel: 020 7831 5162 Fax: 020 7831 4041
e-mail: secretariat@bssh.ac.uk

OFFICERS 2011

President:

D A McGrouther

Immediate Past President:

J S Watson

Vice President:

I A Trail

Honorary Secretary:

D J Shewring

Honorary Treasurer:

R Savage

Editor in Chief:

J J Dias

Council Members:

A N M Fleming

S M Fullilove

C Heras-Palou

J L Hobby

M Hobson

B Jemec

R L Lester

I S H McNab

OUTLINE PROGRAMME**SCIENTIFIC MEETING : 31 MARCH/1 APRIL 2011****Thursday, 31st March**

- 08:30 Registration and Refreshments
- 09:00 Free Paper Session 1
- 10:45 Refreshments and Trade Exhibitions
- 11:15 Free Paper Session 2
- 13:00 Lunch and Trade Exhibitions
- 14:00 Symposium: State of the Art in Tendon Surgery
- 15:45 Refreshments and Trade Exhibitions
- 16:15 Keynote Lecture: Perils in Hand Surgery - Dr D Lalonde
- 16:50 Phalangeal Fractures: How I do it – Dr D Lalonde/Mr D J Shewring
- 17:10 Close
- 17:15 Business Meeting (open to Members and Associates only)
- 19:15
for
20:00 Society Buffet Supper – Imperial War Museum North

Friday, 1st April

- 07:15 Instructional Course on Collagenase (register at Pfizer stand)
- 08:30 Registration
- 09:00 Symposium: Your Hand Practice – Present and Future (Part 1)
- 10:20 Refreshments and Trade Exhibitions
- 10:50 Symposium: Your Hand Practice – Present and Future (Part 2)
- 12:30 Lunch and Trade Exhibitions
- 13:30 Free Paper Session 3
- 15:55 Closing Remarks
- 16:00 Close of Meeting

NOTES

THURSDAY, 31 MARCH

08:30 Registration and Refreshments

Free Paper Session 1

Chairman: Mr D J Shewring/Mr S L Knight

09:00 **Donor site morbidity in free non-vascularised toe phalangeal transfer**

Dr L Garagnani, Dr M Gibson, Miss G Smith (London)

Introduction and Aims: Free non-vascularised toe phalangeal transfer is an established surgical option for reconstruction of hypoplastic digits. This study has assessed donor site morbidity.

Methods: Between 1991 and 2007, forty children with hypoplastic digits underwent free non-vascularised toe phalangeal transfer. The diagnosis was symbrachydactyly in thirty-three cases, constriction ring syndrome in three cases, thumb hypoplasia in three cases and perinatal subclavian venous thrombosis in one case. The patients were followed up for a minimum of thirty-six months following surgery. Mean follow-up was 121.6 months. Toe length ratio, presence of visible deformity and stability of the donor toes were assessed. The Oxford Ankle Foot Questionnaire was administered to patients and families.

Results: This study has shown increasing foot deformity with age, which in some cases has led to significant cosmetic deterioration, especially in cases where multiple donor toes have been used. All patients have floppy unstable toes with visible deformity at long term follow-up. Distal phalangeal hypoplasia has also been identified in our patients. Donor sites worsen progressively with growth.

Conclusions: Donor site morbidity in free toe phalangeal transfer should be taken into account during surgical decision making for reconstruction of hypoplastic digits. Pre-operative counselling with parents and children should include discussion on the possible consequences of phalangeal harvest on donor toes.

09:05 Discussion

09:08 **An analysis of outcome following correction of simple and complex syndactyly of the hand**

Mr N T J Hamnett, Miss K Nelson, Mr W Holmes, Mr A Mishra, Mr M Nixon, Professor P McArthur (Liverpool)

Introduction: The purpose of this study was to comprehensively evaluate syndactyly correction. Patient selection, complexity, technique and aftercare are compared with scar quality, web-creep, hand function and patient satisfaction.

Methods: Eighty-three syndactyly patients (1999-2010) were invited to service evaluation clinics. Complexity, surgical technique (island web transfer, graftless and full thickness skin graft) and aftercare were identified from case notes. Patient satisfaction was obtained via questionnaire. A thirty-minute consultation assessed healing and hand function.

Results: Thirty-four patients (58 webs) attended the assessment. Seventeen were simple syndactyly and 16 complex. The mean age at presentation was 28 months (0-11yrs), follow-up was 28 months (1m-11yrs) and age at operation was 30 months (2 months-14yrs). In the unilateral syndactyly there was no significant difference between web abduction angle on the affected compared to the unaffected sides ($p=0.56$). No significant difference in tip-to-tip distance was observed ($p=0.33$). Creep was strictly assessed using an objective four-point web-creep scale. Of the techniques used graftless techniques had a significantly better range of abduction ($p=0.047$). The grafted had less creep but the graftless had no pigmentation or hair bearing grafts. Nine webs required revision. In all, 96% of patients reported a high degree of satisfaction.

Conclusion: To our knowledge this is the first extensive study that reviews this number of patients with both simple and complex syndactyly using the three different surgical techniques. The study assessed objective outcome measures and provides data that will aid to further improvement of syndactyly services.

NOTES

THURSDAY, 31 MARCH

09:18 Discussion

09:23 **Patient satisfaction following simple and complex syndactyly release**

Mr N T J Hamnett, Miss K Nelson, Mr W Holmes, Mr A Mishra, Mr M Nixon, Professor P McArthur (Liverpool)

Background: Standard assessments of outcome in syndactyly usually assess scar quality, web creep and range of movement. Ultimately the most important factor is patient and parent satisfaction. The aim was to discover if a true correlation exists between formal professional assessment of outcome and patient/parent satisfaction.

Method: Patients who had syndactyly release from 1999-2010 were invited for assessment; thirty-four attended. Anonymised questionnaires were issued. General satisfaction, satisfaction with appearance, dexterity, likelihood of being noticed by peers, rehabilitation and objective success of the operation were assessed (POSAS - patient and observer scar assessment scale/web creep/range of motion/power). Statistical analysis was performed.

Results: In general, 96% of patients were satisfied or very satisfied with the service offered. Two patients with complex syndactyly were unsatisfied to some extent. Patients with complex syndactyly were more likely to be very happy with their outcome than those with simple. There was no significant difference ($p=0.67$, chi sq) between patient satisfaction having either graft or graftless techniques. Patients with web creep were less satisfied ($p=0.01$, chi sq). However, POSAS showed no significant difference ($p=0.61$, ANOVA) in overall satisfaction.

Conclusion: Interestingly patient satisfaction was not dependant on which form of syndactyly the patient suffered from nor which technique was used. Although patients that were assessed as having web creep seemed less satisfied, this was not true in relation to their overall POSAS. Although objective surgical outcome measures are important to us as hand surgeons, ultimately parent/patient satisfaction is based upon more basic social observations.

09:28 Discussion

09:31 **Ultrasound guidance of Botox injection for upper limb spasticity - Alder Hey experience**

Mr A Mishra, Ms S McNally, Ms B Husein, Ms K Littler, Dr R Kumar, Professor P McArthur (Liverpool)

Introduction: Botulinum toxin has an established role in treating spastic disorders. In children with cerebral palsy inadequate treatment results in reduced and deficient muscle growth, causing pain and progressive deformity. There is increased emphasis on accurate localisation and injection to improve functional outcomes due to greater family and patient expectations. Ultrasound (USS) guidance of botulinum toxin injection has been reported since 2002. Alternative techniques include EMG or palpation of muscle mass to identify the muscle. We describe our experience of the use of USS guided Botox injection.

Methods: We retrospectively reviewed case notes of one hundred and fifteen children treated with USS guided Botox between 2004-2010. The assessment tool for end-point measurement used was the Abilhand-Kids questionnaire and VAS. We used a multi-level and multi-site technique, targeting different limb levels and sites within muscles at the elbow, wrist and finger flexors. The dose range was 4-20 iu/kg.

Results: Mean age at first injection was eleven years (range 3-16 years). In sixteen cases both upper limbs were treated simultaneously. Thirty-nine children required a second injection cycle. Mean time to re-injection was twelve months (3-40). Eleven children required a third course at a mean time of thirty-four months (5-53) following previous injection. Functional improvement was used to assess the response.

Conclusion: Ultrasound guided Botox allows effective and safe treatment by easy localisation and targeting of muscle groups thus allowing minimal dosage of drug to be administered. Measuring and providing sustained functional improvement, however, remains debated, and larger clinical trials are required to assess these tools further.

09:36 Discussion

NOTES

THURSDAY, 31 MARCH

09:39 **Management of Madelungs deformity in the skeletally immature adolescents**
Mr M F Nixon, Mr A Mishra, Mr S Nayagam, Professor P McArthur (Liverpool)

Background: Management of Madelungs deformity is shifting towards prevention of deformity with corrective procedures during adolescents.

Methods: We reviewed the management of eighteen wrists in ten patients with Madelungs deformity. 80% of cases were bilateral and all occurred in females. All were skeletally immature at presentation (mean age 11 yrs, range 8 to 18).

Results: 94% were idiopathic (although 35% had a genetic predisposition), one (6%) was secondary to infection. None gave a history of significant trauma. 78% presented with a significant deformity, 53% with restricted motion and 22% with significant pain. 46% had restriction of activities of daily living.

Treatment Algorithm: Patients with minimal symptoms are treated conservatively (7 pts, 39%). Symptomatic patients with significant radial shortening are either treated with distraction osteogenesis (2 pts, 11%) or ulna epiphysiodesis (3 pts, 17%). Symptomatic patients with good radial growth potential are treated with physeal bar separation and fat interposition (Vickers procedure, 6 pts, 33%). All patients treated surgically were satisfied. One patient suffered transient median neuropraxia following the Vickers procedure and one patient was noted to have wrist OA following ilizarov distraction (although this was present pre-operatively).

Conclusion: Adolescent Madelungs can be managed successfully with a variety of surgical procedures.

09:44 Discussion

Bell Session

09:47 **Chemotherapy for aggressive infantile digital fibromatosis secondary to syndactyly release**
Mr A Barabas, Mr A N M Fleming (London)

Introduction: Correction of complex syn-polydactyly of the right index and middle fingers was performed in a one year old boy. Within months nodular fibroses developed along the middle finger, which were excised, with histology confirming infantile digital fibromatosis (IDF). The fibrosis rapidly recurred resulting in pain and deformity. At age three tumour excision and third ray amputation was performed, to relieve pain, and adjunctive steroid injections given for a year - with little impact. Florid recurrence occurred over the central hand, restricting finger movement and referral was made to paediatric oncology.

Methods and Results: After international opinion was sought, a trial of chemotherapy was instituted. A weekly regime of vinblastine and methotrexate over fifteen weeks was instituted. This resulted in dramatic shrinkage of the tumour, the pain subsided and he has significantly improved function of the hand.

Discussion and Conclusion: IDF occurs in the fingers and toes of infants. These lesions usually manifest as hard nodules of spontaneous onset involving the extensor surfaces, most commonly the dorsal and lateral aspect of the distal or middle phalanx. Spontaneous regression occurs in most un-operated cases. Differential diagnosis of keloid scar and unknown tumour often leads to inappropriate surgery with rapid recurrence. We are not aware of this association between appropriate surgery, for syndactyly, and the occurrence of such aggressive IDF. In severe cases, such as this, chemotherapy may halt and even reverse the disease process.

09:49 **Flexor pollicis longus injury in children and infants**
Mr M Gorman, Mr M A A Khan, Mr J Wiper, Mr A J Platt (Hull)

Aim: To present our series of seven paediatric flexor pollicis longus (FPL) tendon injuries over a seven-year period. Digital flexor tendon injuries in children are uncommon and those involving the thumb are rare. The unique anatomy of the FPL tendon, its improved vascularity in children and age related issues with compliance have led to variations in operative techniques and post-operative regimes. We discuss our cases and potential modifications to hand therapy regimes in this cohort of patients.

NOTES

THURSDAY, 31 MARCH

Methods: A retrospective review of medical case notes and hand therapy assessment charts to document presentation, associated injuries, initial management, timing of surgery, grade of surgeon, type of repair and post-operative rehabilitation. Three patients underwent recommended early active mobilisation. Three patients wore splints, but were not compliant with hand therapy. One infant required immobilisation with a boxing-glove splint. This allowed a comparison between early mobilisation versus modifications based on patient age and compliance. Mean follow-up was four years.

Results: Final results were objectively evaluated using a modified Kapandji scale. In six patients results were graded as good to excellent. In one patient with a suspected re-rupture, a functional restriction associated with a 45° IPJ flexion deficit. Concurrent injury, zone of injury and early mobilisation did not have a negative effect on outcomes.

Conclusions: We conclude that although uncommon, FPL injuries in children require appropriate and timely surgical intervention combined with specialist, patient-specific modifications to post-operative hand therapy regimes for a good functional outcome.

09:51

A novel technique of flexor tendon reconstruction using fascia lata graft*Mr A Molajo, Mr A Mishra, Mr A Iqbal (Liverpool)*

Introduction: We present a novel technique of flexor digitorum profundus (FDP) reconstruction in a deficient palmaris longus patient. The plantaris muscle was very thin and unsuitable for reconstruction. A fascia lata graft was harvested and fashioned to reconstruct the FDP tendon to the left ring finger.

Methods: A thirty year old right hand dominant with FDP injury secondary to glass laceration in zone 3 of his left ring finger who previously had first stage tendon rod, presented very late for second stage after four years. He was counselled on the risks and benefits of reconstruction. At surgery the previous wounds were explored. The proximal stump was significantly scarred with minimal excursion. Palmaris longus was absent and plantaris was small and too thin for reconstruction. A strip of fascia lata was harvested from the right thigh using a tendon stripper and was gently twisted after doubling up for tendon reconstruction. The harvested graft was secured to the remnant FDP tendon distally and proximally with a Pulvertaft weave.

Results: The patient commenced early active mobilisation under close supervision of the specialist hand therapists. He has had no problems with his rehabilitation to date. He is satisfied with his surgery.

Conclusion: This case demonstrates a viable alternative to palmaris longus or plantaris reconstruction of the flexor tendon. This is useful as patients may have an absent or deficient palmaris longus or plantaris. Early results seem to be encouraging. This technique is a valuable alternative when palmaris or plantaris tendon reconstruction is not appropriate.

09:53

Long flexor versus intrinsic dominance - A comparison of flexion spirals*Mr J Seaward, Mr B Shatta, Ms F Peck, Miss V C Lees (Manchester)*

Aims: Finger flexion is a composite movement, involving both long flexors and intrinsic hand muscles. Previous studies describe the flexion curve as a 'Golden Spiral'. We hypothesise there are differences in the flexion curve between individuals, dependent on dominance of long flexors or intrinsic muscles. Hand rehabilitation is key following flexor tendon injury, but current regimes concentrate on finger flexion using long flexor muscles. This pilot study investigates whether flexion curve differences exist between individuals so that, if true, rehabilitation regimes can be developed to better serve individuals who are 'Intrinsic Dominant'.

Methods: Twelve volunteers repeatedly flexed and extended all fingers at a comfortable speed, resting their hand on a horizontal surface and video was recorded from the ulnar border, perpendicular to the little finger flexion plane. Little finger tip position was identified frame-by-frame to create a composite curve and its highest point was noted (XH). The horizontal distance between proximal finger crease and XH was measured (?XH). Two investigators independently reviewed frame-by-frame images and allocated subjects into 'Long Flexor Dominant' and 'Intrinsic Dominant' groups. Non-parametric statistical analysis was performed with a null hypothesis that there is no difference in ?XH between groups.

NOTES

THURSDAY, 31 MARCH

Results: ?XH demonstrated two clusters, consistent with our hypothesis. There was a statistically significant ($p < 0.036$) difference between groups.

Conclusion: Our study demonstrates that qualitative and quantitative differences exist in finger flexion curves between individuals. Further study of differences between individuals, prevalence of each curve type and differences in outcome following flexor tendon injury in each group is warranted.

09:55

Predicting risk of flexor pollicis longus tendon rupture after volar plating - The role of post-operative radiographs

Mr D Selvan, Mr D Perry, Mr D Brown (Liverpool)

Introduction: Pollicis longus (FPL) rupture has been described as a relatively common complication following volar plating of distal radius fractures. The aim of the study was to investigate the possible relation between parameters measured on post-operative radiographs and the occurrence of FPL ruptures. There is no current literature on this subject to our knowledge.

Methods: Eleven patients with FPL ruptures after volar plating with four different plate systems were identified. These were case matched to twenty-two control patients, treated with the same plate systems, with no flexor tendon symptoms or signs at one year post surgery. Five assessors, who were all blinded to the patient groups, assessed all 33 post-operative radiographs. Fracture reduction was assessed using volar tilt, radial tilt, radial height and ulna variance. Plate position was assessed using angulation of the plate, distance of plate from the joint and translation from mid-line. All of these were calculated using a template.

Results: In relation to fracture reduction; volar tilt and radial tilt were statistically significantly different between the FPL rupture and normal groups while radial height and ulna variance were not. In relation to plate position; the plate angle and the length of the plate from the joint were statistically significantly different while translation was not.

Conclusions: The accuracy of fracture reduction and plate placement are related to the likelihood of FPL rupture. These are under the control of the operating surgeon. Less than perfect post-operative radiographic appearances warrant close surveillance and consideration of early metalwork removal.

09:57

Free vascularized fibula for the treatment of bone defects and nonunion of the radius and ulna: A staged reconstruction protocol

Mr A Mishra, Mr A Molajo, Mr H Shalaby, Mr K Graham, Mr S Nayagam (Liverpool)

Introduction: Segmental bone defects of the radius or ulna can be managed by bone grafting but defects greater than 6cm are difficult to treat with these conventional techniques. Restoring the length relationships between forearm bones is important for stability and function of the distal radio-ulnar joint.

Methods: A retrospective review of patients with bony defects of either radius or ulna treated with a staged protocol was conducted. There were nineteen patients between 2004-2009; fifteen had radial and four had ulnar bone defects treated. The mean age was thirty-nine years. The mean follow-up period was fifty-two months. The bony defect measured a mean of 7.6cm. The patients underwent a two-stage reconstruction procedure: radical debridement and the dead space management using Gentamicin spacers. An external fixator was applied across the defect to gradually restore the length of the affected bone. At the second stage the contralateral fibula, based on a peroneal vascular pedicle, was harvested with an area of overlying skin supplied by perforating vessels and held within the defect using internal fixation.

Results: Bony union occurred at a mean of 4.5 months. One patient required further surgical intervention to achieve union. The pre-operative elbow and wrist range of movements were preserved in all patients. One patient had a graft fracture at four months; this healed with cast support. No implant failure, recurrence of infection or formation of synostosis was encountered.

Conclusion: The staged reconstruction, utilising external fixation followed by vascularised fibula grafts, is an effective treatment of composite defects of the forearm.

10:02

Discussion

NOTES

THURSDAY, 31 MARCH

10:05 **A prospective study of the safety and efficacy of forearm tourniquets in elective hand surgery performed under local anaesthesia**
Mr K Kok, Miss E Chipp, Mr A Lahiri (Birmingham)

Introduction: Upper limb surgery requires a tourniquet to maintain a bloodless field. We aimed to study efficacy, patient discomfort and complications in routinely performed local anaesthetic hand surgery using a forearm tourniquet.

Methods: Local anaesthetic elective hand surgery cases performed with a forearm tourniquet over three months (March-May 2010) were studied prospectively. A proximal forearm tourniquet was applied with a pressure of 220mm Hg. Tourniquet efficacy was evaluated subjectively and discomfort during and following the procedure was assessed. Patients were followed up to rule out delayed complications.

Results: Fifty-two cases were performed with 32 males and 20 females. The mean age was 60.6 years (Range 18-89). The case mix is as follows :

Cases	Number
Carpal tunnel decompression (CTD)	28
Release of trigger finger	13
Combined CTD & trigger finger release	3
Mucous cyst excision	3
Excision ganglion	2
Excision pyogenic granuloma	1
Excision of gouty tophus	1
Limited fasciectomy for Dupuytren's	1

The mean tourniquet time was 7.22 minutes (range 4-21 minutes). The forearm tourniquet never exceeded 21 minutes and maintained a bloodless field in all cases. The tourniquet was well tolerated with no immediate or delayed complications.

Conclusions: Our study confirms the findings that the forearm tourniquet is safe, efficacious and well tolerated by patients undergoing local anaesthetic elective hand procedures lasting twenty minutes or less and can be used instead of the upper arm tourniquet. For procedures likely to last longer than twenty minutes, we continue to use the upper arm tourniquet with regional or general anaesthesia.

10:10 Discussion

Bell Session

10:13 **The pressure under finger tourniquets**
Dr S Middleton, Mr P Jenkins, Mr R Anakwe, Mr A Muir, Miss J McEachan (Dunfermline)

Aims: The National Patient Safety Agency (NPSA) issued a rapid response report in December 2009 that recommended the use of CE marked finger tourniquets and banned the use of surgical gloves for this purpose. This study aimed to measure the surface pressures produced beneath digital tourniquets.

Materials and Methods: A Tekscan FlexiForce® pressure sensor was used to measure the surface pressures under different types of finger tourniquet. The tourniquets tested were the Toe-niquet™, the T-Ring™ and a tourniquet made using a rolled up surgical glove finger.

Results: The pressure exerted by these tourniquets varied between types and depended on the size of model finger. The lowest mean pressures were produced by the T-Ring™ and glove finger tourniquet on a small finger (146 and 120 mmHg), while the highest pressures were produced by the Toe-niquet™, which produced 663 and 1560mm Hg on the small and large finger models respectively. There was a significant overall difference between tourniquet type ($p < 0.001$) and finger size ($p < 0.001$).

Conclusions: Wide variability in surface pressures is a function of material type, product design and finger size. It is difficult to anticipate and regulate pressures generated by non-pneumatic tourniquets. Safe limits of application time and pressure are unclear.

NOTES

THURSDAY, 31 MARCH

10:15

Simulator based operative plastic surgery skills training - An affordable and successful course model
Mr S Majumder, Mr R Pinder, Miss E George, Mr U Anwar, Miss A Murray, Mr S Southern (Wakefield)

Plastic surgery is a technique based specialty. The plastic surgical trainee needs to acquire a "toolbox" of fundamental plastic surgical skills, mastery of which is essential to solve a wide variety of reconstructive challenges, from the simple to the very complex.

Increasingly, reduced working hours are being imposed on surgical trainees. Unfortunately, this has meant that the traditional apprenticeship based model of operative skills training, as the sole training delivery system, can no longer be considered adequate.

To worsen matters, restricted educational budgets make many cadaver based courses in operative surgery prohibitively expensive for many plastic surgery trainees.

To ensure that tradition of excellence in operative surgical training in plastic surgery is maintained, innovative ideas have to be explored.

We present our experience of having developed a very successful, "within budget" plastic surgery operative skills course which is entirely simulator based. The course, using a variety of inexpensive, custom built, realistic simulators, affords the delegates extensive hands-on practical training in fundamental plastic surgical skills such as:

- suturing techniques
- skin grafting
- skin flaps
- tendon repair
- hand fracture fixation
- basic microsurgery technique inc. nerve repair (using loupe magnification)

Simulator based plastic surgical skills training has an expanding role as an adjunct to traditional training methods. We assert that there is a need for more simulator based plastic surgery skills courses to be developed. In addition there is a need for skills training centres, with suitable simulators to be readily accessible to all plastic surgery trainees.

10:17

Alcohol hand gels: Commonly used, but are they effective?*Mr M Singh, Mr J Rodrigues, Mr P Loughenbury, Mr W De Jager (Bradford)*

Introduction: *Reducing hospital-associated infection is a clinical priority. Local policies may advocate alcohol hand gels as part of this. As hand surgeons examine large numbers of patients, they require effective hand hygiene techniques with minimal dermatitis reactions. We review the evidence for the efficacy of alcohol gels and irritation caused by them.*

Methods: *OvidMEDLINE was searched for "alcohol" and "handwashing" and "gels". English abstracts were reviewed and full papers of relevant articles were analysed.*

Results: *Twenty-six results were identified, of which four were relevant. All were obtained. Kramer et al tested the efficacy of common alcohol gels against EN1500 (European standard for activity against E. coli) compared to a reference alcohol, and found all to be below the standard. They suggested that alcohol gels were less effective than hand washing.*

Kampf et al tested a newer alcohol gel comprising 85% ethanol. They found it met the EN1500 standard within thirty seconds of application. Positive feedback was obtained from users, suggesting the gel was well tolerated. A further paper by Kampf investigated dermatological impact of gel use, showing that up to 30% of users may develop dermatitis. However, this risk was attenuated by the addition of emollients.

Löffler et al found that hand gels with emollients were less irritant than washing with water and detergents.

Conclusions: *Hand surgeons should review the alcohol gel provided where they work. If it does not comprise a high alcohol percentage with emollient incorporated or available, then hand washing may remain preferable in clinical practice.*

NOTES

THURSDAY, 31 MARCH

10:19

Second pathology in carpal tunnel syndrome patients

Mr J Pollock, Dr J Muzaffar, Dr A Hay-David, Mr S Southern (Wakefield)

Introduction and Aims: Carpal tunnel syndrome (CTS) is the most common peripheral nerve entrapment neuropathy, but in our experience patients referred with CTS can frequently have other hand pathology. Recent changes in referral patterns have resulted in patients bypassing surgical outpatient appointments via a fast-track referral from the GP. Our study aimed to establish what proportion of patients referred for CTS to a specialist hand surgery unit were also found to have a second pathology.

Methods: We conducted a retrospective case note analysis of one hundred consecutive patients undergoing surgical carpal tunnel decompression in our hand surgery unit after assessment in out-patient clinic. This was compared to one hundred consecutive patients seen in non-hand specialist clinics or fast-tracked to theatre. Notes were examined for details of additional hand pathologies documented in clinic notes and operative records.

Results: The majority of patients with carpal tunnel syndrome seen through the hand service had a second diagnosis, over half of which required operative intervention. These diagnoses included Dupuytren's contracture, ganglions, rheumatoid arthritis, cubital tunnel syndrome and first CMCJ arthritis. This contrasts with the patients seen by the fast-track service who had a 0% second diagnosis rate.

Conclusions: This study shows that a significant number of patients referred with CTS also have further hand pathology which requires operative intervention. This shows that the fast-track, production line treatment of CTS should be discouraged as it fails to treat the patient holistically. Patients with CTS should be seen and assessed by a specialist hand service prior to any operative intervention.

10:21

Ulnar clasped hand - Radical surgery for an intractable problem

Mr O Harley, Mr A N M Fleming (London)

Introduction and Aims: Ulnar clasped hand (syn. clenched fist syndrome) is an obscure chronic progressive flexion contracture of the ulnar 2-3 fingers, invariably seen in older female patients with no underlying nerve or tendon injury or rheumatological disease. It has been associated with psychiatric disease and trivial trauma. It results in excluded ulnar fingers with absent grip, hygiene and infection concerns secondary to palm maceration.

Material and Methods: Four female patients, mean age 68, presented after between 0 and 4 procedures done by other surgeons with recurrent, mostly fixed, flexion deformities at the level of the metacarpophalangeal and proximal inter-phalangeal joints. These previous procedures included trigger releases (3), flexor tenolyses (2), joint release (2), Dupuytren's release (2) and MUA (2). All had prolonged hand therapy and splintage but all deformities had become recurrent. None had any diagnosed psychiatric condition. Three patients have come to radical surgery and one has declined. A single stage progressive release is undertaken: this commences with zone 5 fractional flexor lengthening in the musculo-tendinous junction and proceeds to combinations of arthrodesis and/or arthroplasty at the MCPJ and PIPJ levels. The decisions on whether to fuse or replace joints will be discussed.

Results and Statistics: Surgery followed uncomplicated post-operative courses. At a mean follow-up of eight months all ulnar digits are clear of the palm, are again incorporated into hand function and with no sign of recurrent progressive flexion. We will present average range of motion for arthroplastied joints and average position on arthrodesed joints. DASH scores have been completed.

Conclusions and Clinical Reference: This is an uncommon but fraught condition for which a single stage radical operation produces a functional hand.

10:26

Discussion

10:29

A review of 417 cutaneous malignancies of the hand

Mr S Maciburko, Mr W Townley, Dr S Matousek, Mr H Giele (Oxford)

Introduction: The hand is an uncommon site for cutaneous malignancies, and tumour management and reconstruction can present a challenge. The purpose of this study was to characterise the natural history, surgical management and outcome of skin tumours affecting the hand.

NOTES

THURSDAY, 31 MARCH

Methods: We performed a retrospective review of patients who had excision of cutaneous hand malignancies at the John Radcliffe Hospital between 1993 and 2010. Histopathological reports and case notes were analysed to determine patient demographics, risk factors, surgical management, tumour characteristics and outcome.

Results: Four hundred and seventeen lesions were excised from 300 patients (mean age 75, 60% male). SCC was the most common tumour (n=344) followed by BCC (35) and malignant melanoma (MM)(22). The most common site was the dorsum of the hand. Fifty-eight percent of defects required soft tissue reconstruction (40% skin graft, 16% local flap, 2% free flap). Seventeen percent of patients had multiple hand tumours. Regional lymphatic spread occurred in 36% of MM patients and 7% of SCC patients. Distant metastatic spread occurred in 32% of MM patients and 0.4% of SCC patients. Death occurred in four of 22 MM patients (18%) and in 3 of 227 SCC patients (1%).

Conclusions: We present a large series detailing the management and outcome of cutaneous hand malignancies. Most defects required soft tissue reconstruction with a graft or flap. SCC was by far the most common lesion, although metastatic dissemination was very rare. BCC occurred infrequently. Melanoma was rare but presented at an advanced stage and was associated with a poor prognosis.

10:39 Discussion

10:45 Refreshments and Trade Exhibitions

Free Paper Session 2

Chairman: Mr R Savage/Mr R H Milner

11:15 **Primary repair of Zone 1 flexor tendon injuries**

Mr A Bidwai, Miss L Feldberg (Liverpool)

Introduction: We present the results for primary tendon repair of Zone 1 flexor tendon divisions amenable to primary repair distal to and proximal/just under the A4 pulley between 1997 and 2007.

Methods: Eighty-two patients were treated by primary suture repair for Zone 1 flexor tendon injuries over a ten-year period, for which outcome data is collected by hand therapists as part of a prospective flexor tendon repair audit. Retrospective case note review was performed to determine incidence of post-operative surgical complications and subsequent re-operations.

Results: Sixty-nine patients (85%) completed 12 weeks follow-up post-surgery. Of these patients sixty-five achieved excellent results in terms of Total Active Movement (TAM) as described in Strickland's modified criteria. However when assessing range of motion at the Distal Interphalangeal Joint (DIPJ) as described by Moiemmen and Elliot only four patients could be classified as having an excellent outcome at twelve weeks. 19% of patients developed a complication, most significantly repair rupture in three patients and stiffness/contracture in nine patients, five of which went on to have further surgery.

Conclusions: In this study of eighty-two patients who underwent primary repair for Zone 1 flexor tendon repair, the rate of complications is 19%. Additionally our results support the current literature in stating that range of motion at the DIPJ is more indicative of the result of surgery, given that when using TAM as an outcome measure almost all patients are rated as excellent at twelve and 26 weeks.

11:25 Discussion

11:30 **Shirt-button over the nail technique for the treatment of Zone 1 flexor tendon injuries**

Mr A Bidwai, Miss L Feldberg (Liverpool)

Introduction: The standard method for treatment of Zone 1 flexor tendon injuries in our unit is the shirt-button over the nail technique. In light of recently published studies demonstrating significant morbidity associated with the technique, we felt it was of value to audit our results with this technique.

Methods: Thirty-six patients were treated with shirt-button technique for Zone 1 flexor tendon injuries between 1997-2007, for which outcome data is collected by hand therapists as part of a prospective flexor tendon repair audit. Retrospective case note review was performed to determine incidence of post-operative surgical complications and subsequent re-operations.

NOTES

THURSDAY, 31 MARCH

Results: Thirty-one patients (86%) completed 12 weeks follow-up post-surgery. Of these, thirty patients achieved excellent results in terms of Total Active Movement as described in Strickland's modified criteria. However when assessing range of motion at the distal interphalangeal joint (DIPJ) as described by Moiemmen and Elliot, only one patient could be classified as having an excellent outcome at 12 weeks. Only one patient had a post-operative complication directly related to the shirt button technique, a superficial infection that responded to oral antibiotics.

Conclusions: In this study of thirty-six patients over a ten-year period the complications directly related to the use of the shirt-button technique for Zone 1 flexor tendon injury are infrequent. This finding is not consistent with findings in recently reported series, and the shirt-button technique remains our primary method of treatment for these injuries.

11:35 Discussion

11:38 **Arthrodesis of the distal interphalangeal joint and thumb interphalangeal joint using a headless compressive screw (Mini-Acutrak®): A review of clinical outcome and complications**

Dr A Das, Mr S Konan, Miss E Taylor, Mr E Sorene (London)

Introduction: Distal interphalangeal joint (DIPJ) or thumb interphalangeal joint arthrodesis is a recognised treatment for restoring joint stability and hand function. The aim of this study was to review the clinical outcome and complications in patients who underwent DIPJ fusion using an axial screw with variable thread pitch, the Mini-Acutrak® screw (Acumed, LLC, Hillsboro, OR, USA).

Method: Twenty-one cases of DIPJ arthrodesis were performed using the axial Mini-Acutrak® screw. Thirteen patients with painful osteoarthritis and eight with traumatic osteoarthritis. Patients were followed up until radiological union was confirmed and desired functional result was achieved. Patient satisfaction, the Quick Disability of the Arm, Shoulder and Hand (quick-DASH) score and radiographs were assessed at final follow-up.

Results: All patients tolerated the procedure well. Eighteen patients (86% of cohort) achieved a quick DASH score of less than 30, consistent with an excellent functional outcome. Radiological union was confirmed in all these cases at three-month follow-up. Four complications were noted. One case of distal bone fracture and one case of screw migration were treated conservatively and did not affect the final outcome. One patient had screw cut-out and required revision to k-wire. One patient required screw removal for infection at four weeks but progressed to union with conservative management.

Conclusion: The use of axial mini-Acutrak® screw for DIPJ and thumb arthrodesis has been associated with excellent clinical and functional results in our cohort. This adds to the evidence that this technique is a safe and effective means of restoring joint stability.

11:43 Discussion

11:46 **How do patients fare after pyogenic flexor tenosynovitis? The Bradford experience**

Mr D Nikkhah, Mr J Rodrigues, Miss Y Ahmed, Mr P Loughenbury, Mr W De Jager (Bradford)

Introduction: We report outcomes and learning points from a one-year series of flexor sheath infections (FSIs) presenting to a typical UK hand unit.

Methods: Between August 2009 and August 2010, sixteen FSIs were confirmed from operation note documentation. All case notes were reviewed, and all patients were sent a quickDASH questionnaire.

Findings: Patient age varied between twelve and 82 years. 38% were manual labourers. Over 60% of cases were secondary to bites (human/animal) or open wounds. 25% of cases had no triggering event. All patients presented within 48 hours of onset of symptoms. Fusiform swelling and pain over the flexor sheath were the most consistent clinical findings. All patients had either Michon grade 1 or 2 infections, and underwent surgery within twenty-four hours via distal and palmar incisions, with 0.9% Saline irrigation. Operations were performed under general anaesthetic, except for one case (median nerve block). 69% required one washout in theatre, 19% needed two washouts and 12% three washouts. Beta-haemolytic streptococcus was confirmed in two cases, and was associated with multiple operations and prolonged admission (up to 9 days). 44% of patients completed the questionnaire, with a mean quickDASH of 7.14. Return to work ranged from two to eight weeks.

NOTES

THURSDAY, 31 MARCH

Conclusions: FSI should still be suspected even without triggering events. Kanavel's signs remain diagnostically useful. When treated within seventy-two hours of symptom onset, most patients may only require one washout in theatre and achieve a good outcome. Close liaison with microbiology and early identification of beta-haemolytic streptococcus may predict the need for multiple washouts.

11:51 Discussion

Bell Session11:54 **Single K-wire static distraction device for paediatric phalangeal fractures***Mr A Molajo, Miss B Husein, Mr P Vaiude, Mr C Duncan (Liverpool)*

Introduction: We present a case series of paediatric phalangeal fractures managed by a novel static in-line distraction system requiring only one Kirschner wire (K-wire). Traditionally dynamic distraction splints were configured using two K-wires. Such systems allow in-line distraction whilst achieving early active mobilisation. The advantage of our technique is it reduces the metalwork by 50% therefore reducing the associated complications. This technique is particularly suitable for paediatric patients as the rehabilitation potential following immobilisation is found to be greater than in adults.

Methods: Three children were treated using this technique (2 intra-articular and 1 extra-articular phalangeal fractures). Mean age of patients eleven (range 8-14). The fractures were reduced and K-wired under radiological control to ensure accuracy of insertion and preservation of the epiphyseal plate. The exterior portions of the K-wire were bent parallel with the axis of the digit. A pre-fabricated thermoplastic splint was secured to the hand. Rubber bands were used to apply traction.

Results: Mean time to union twenty-five days (range 17-41 days). Follow-up radiographs showed radiological evidence of bone union. Clinically the fractures were pain-free on testing with no rotational deformity. All patients were referred to physiotherapy to maximise rehabilitation potential.

Conclusion: Our device produces good radiological and clinical outcomes in the paediatric injury group. We would suggest that it is considered in this group of patients with intra or extra-articular fractures of the proximal and middle phalanges. A co-operative patient with adequate family support to tolerate the device and comply with rehabilitation is essential.

11:56 **Referral patterns and diagnostic accuracy of hand trauma in the emergency department***Miss R Zakeri, Dr J Costello (London)*

Introduction: Hand trauma typically represents 20% of emergency department (ED) attendance. Early treatment in an appropriate setting is crucial to ensure successful outcomes. In a plastic surgery tertiary referral centre, we evaluated the propriety of referrals from the ED to hand trauma service (HTS). This study aimed to appraise diagnostic accuracy in the ED to construct guidelines for appropriate hand trauma care.

Methods: Case records for all patients presenting to the ED with hand injuries across a two-month period were retrospectively reviewed. Patients referred to HTS were identified and analysed regarding type of injury, ED and HTS diagnoses, and location of definitive management.

Results: Forty-four cases (25%) were referred for HTS assessment, of which twenty-one were referrals from other regional EDs. Suspected tendon rupture (43%) and closed fractures (25%) were the commonest indications for referral, with injury mechanisms of knife lacerations, crush injuries and falls. Bony injury comprised 50% of cases whilst 11% involved neurovascular impairment. Diagnostic accuracy by the ED was less than HTS (82% versus 95%), particularly localising tendon and nerve damage. Definitive management was carried out in the ED for 11%, but most treatment occurred in day-surgery theatres within four days of presentation.

Conclusions: Most hand injury referrals are of appropriate complexity to warrant specialist assessment and treatment beyond the ED. A low threshold for referral to specialist hand surgeons is advised to ensure more accurate assessment and prompt treatment of complex injuries. We propose guidelines for optimal management of hand trauma between the ED and HTS.

NOTES

THURSDAY, 31 MARCH

11:58

The effect of dorsal angulation on basal fractures of the proximal phalanx as a predictor of functional outcome - A cadaveric study*Miss M Rymaszewska, Mr A Ranganathan, Mr V Kamath, Mr C Coapes, Professor J Stothard (Middlesbrough)*

Introduction: This cadaveric study aims to demonstrate the relationship between dorsal angulation of basal fractures of PPx, and resulting fingertip-palm distance (FPD) in full flexion.

Methods: Length and AP diameters of PPx were measured in ten cadaveric hands (40 digits). Assumption of 90° flexion in each joint was made and role of the soft tissue envelope was not considered. A hypothetical fracture line at a proportionally constant distance (half the AP diameter) from the proximal end of the bone was taken, and resulting FPD calculated for dorsal angulations of 10, 20, 30 and 40 degrees.

Results: The average length of PPx of index, middle, ring and little fingers in male cadavers was 39.9, 47.5, 44.65 and 36.23mm compared to shorter measurements in females at 39.45, 43.52, 38.73 and 33.42mm respectively. Mean FPD for respective fingers with a PPx fracture at 10° dorsal angulation was 6.26, 7.12, 6.52 and 5.46mm, whilst at 20° these values increased to 12.48, 14.17, 13.12 and 10.87mm. The average FPD of the longer fingers with the little finger at 10 and 20 degrees was 6.67: 5.46mm and 13.26: 10.87mm. 40% of little finger PPx fractures achieved FPD of =10mm despite 20° dorsal angulation, whereas 100% of cases affecting the other fingers failed to achieve the same.

Conclusions: The study demonstrates that greater angulations can be tolerated with shorter PPxs and 20° angulation has a detrimental effect on FPD and hence hand function. This could account for a difference in acceptable limits between individual digits and sexes.

12:00

The relationship of Dupuytren's disease with socioeconomic deprivation*Dr S Middleton, Mr P Jenkins, Mr A Watts, Miss J McEachan (Dunfermline)*

Introduction: We aimed to define the incidence of Dupuytren's disease in a well-defined patient population and to investigate any relationship between the incidence of Dupuytren's disease and socioeconomic deprivation.

Material and Methods: We prospectively collected data on all patients referred to our regional hand surgery service during a twelve-month period. From this information and national census data, we calculated the incidence of Dupuytren's disease and assigned social deprivation scores to each patient using the Scottish Index of Multiple Deprivation (SIMD), an established epidemiological tool.

Results: Over a one year period there were one hundred and fifty-five new patients with a diagnosis of Dupuytren's disease. The incidence in males was sixty-four per 100,000 per year compared with 22 per 100,000 in females (OR 2.9, $p < 0.001$). Socioeconomic deprivation also influenced the incidence of Dupuytren's disease. The incidence was sixty-six per 100,000 per year in the most deprived quintile, compared with 33 per 100,000 per year in the least deprived quintile (OR 2.0, $p = 0.006$).

Conclusions: Socioeconomic deprivation is associated with Dupuytren's disease. The nature of this association is unclear, as is the link with underlying risk factors. A causal relationship cannot be inferred, but future research should focus on the relationship of comorbidity, occupation and genetic variation with socioeconomic deprivation.

12:02

Collagen degradation and the expression of proteases involved in collagen metabolism in the contraction of collagen gels by Dupuytren's diseased fibroblasts*Dr J Morris, Dr G Riley, Mr A Chojnowski, Professor I Clark (Norwich)*

Introduction: An imbalance of collagen deposition and degradation contributes to Dupuytren's disease pathology. The major collagen-degrading enzymes are from the matrix metalloproteinase (MMP) family. Our hypothesis is that MMP-1, -8, -13 and -14 and the related enzymes ADAMTS (a disintegrin and metalloproteinase domain with thrombospondin motifs) -2, -3 and -14 contributes to matrix contraction which underlies Dupuytren's pathology.

NOTES

THURSDAY, 31 MARCH

Methods: Fixed fibroblast populated collagen lattice (FPCL) assays were established using fibroblasts derived from the palmar fascia of Dupuytren's disease patients. Collagen lattices developed tension over forty-eight hours, released, and their contraction followed over 24 hours using Image J software. Gels were harvested under tension at twenty-four and 48 hours, then at three hours and 24 hours release. Taqman Low Density Arrays measured expression of MMPs, ADAMTSs and their inhibitors. In parallel, a hydroxyproline assay was performed on the lattice conditioned media to quantify collagen degradation.

Results: Collagen lattices from six Dupuytren's fibroblast lines contracted similarly after release. The Hydroxyproline assay demonstrated that collagen break down occurs concomitant with gel contraction. MMP1 and MMP13 expression increased in collagen gels compared to monolayer culture and this expression further increased as tension developed and then decreased with release. MMP14 expression was minimally altered by tension, but increased upon release. TIMP1 expression was high in these cells and increased with tension.

Conclusion: The expression of a number of proteases involved in collagen metabolism is regulated during collagen gel contraction and release. Collagen degradation takes place despite apparent high expression of inhibitors.

12:04

Can Dupuytren's Disease be assessed more reproducibly?

Mr J Rodrigues, Mr H Salem, Dr M Rodrigues, Mr R Amirfeyz, Professor T R C Davis (Nottingham)

Introduction: Dupuytren's disease is typically assessed by goniometry. This technical skill must be learned, and documentation of measurements is required. We produced and evaluated an assessment tool requiring no training that provides digital photographs as a permanent record of the condition.

Methods: A novel device to assess the severity of contractures was designed. The portable device comprised a metric rule fixed perpendicular to a plate against which the hand metacarpal was held via a Velcro strap. Patients were recruited from hand clinic on a voluntary basis. Two trainees, who had no previous experience of using the device, photographed affected digits independently. Both trainees then performed goniometry of the most severely affected joint of the digit. A blinded observer assessed the photographs. The measurement was the distance between the metacarpal level and the hyponychium. Intraclass correlations were calculated for the pairs of goniometric angles and the novel device distances.

Results: Thirty digits on different hands of 27 patient volunteers were assessed. Twenty-two of 27 were male. Equal numbers of right and left hands were assessed. There were five middle, 7 ring and 18 little fingers. Intraclass correlations were slightly better for the novel device (0.977 versus 0.956), but not significantly so when 95% confidence intervals were assessed.

Conclusions: This novel device can easily be used to obtain assessments of contracture severity that are as reproducible as goniometry. Digital photography allows permanent records to be produced, making this a potentially useful tool for research and clinical practice.

12:06

Efficacy and tolerability of collagenase clostridium histolyticum in patients with Dupuytren's contracture (DC): Results from a multicenter, open-label study

Mr C Bainbridge, Dr A Houston, Dr G Jones, Mr R H Milner, Dr S Wilbrand (Allestree)

Introduction: Injectable collagenase is a novel, non-surgical therapy with efficacy in correcting DC. We evaluated the efficacy and tolerability of five collagenase injections using a protocol designed to follow clinical practice.

Methods: DC patients with primary flexion deformities of 20° received three collagenase (0.58 mg) injections/joint (5 injections/patient) at thirty-day intervals. The primary endpoint was clinical success: reduction in contracture to 5° thirty days after the last injection (Day 30). After the first injection into a prioritised joint, patients could opt to receive two injections into the same cord or cords from other affected joints whether or not they achieved success with the first joint.

NOTES

THURSDAY, 31 MARCH

Results: 71% of MP (n=343) and 41% of PIP joints (n=244) achieved clinical success. Among the remaining joints, 66% of MP (n=100) and 38% of PIP joints (n=144) showed 50% reduction in contracture after collagenase. For range of motion, mean \pm SD increase from baseline to day thirty was $33.0 \pm 16.2^\circ$ for MP and $27.5 \pm 18.5^\circ$ for PIP joints. Common AEs were localised edema, bruising, pain, swelling and tenderness; most resolved without intervention. Two serious AEs, deep vein thrombosis in the leg and tendonitis with partial tendon/ligament injury, were deemed possibly and probably related to treatment, respectively. 87% of patients were Very/Quite Satisfied with their treatment.

Conclusions: Results from this study, designed to follow clinical practice, provide support for the efficacy of collagenase in correcting the flexion deformity of MP/PIP joints caused by DC. Clinical success and improvement rates were comparable to those observed in randomised, placebo-controlled trials.

12:16 Discussion

12:21 **Distal-first dissection for digital Dupuytren's disease**

Miss M Bertleff, Mr D Evans (Windsor)

Introduction: Publications on the surgical management of Dupuytren's contracture have mostly been concerned with types of incision and the extent of fasciectomy. There is little detailed discussion of where to start the dissection, with an apparent assumption that it should start proximally in the palm and work distally. The only mention of distal commencement that we have found is a brief comment by McFarlane in a book chapter. Most publications advocate proximal dissection first.

Methods: Surgical dissection starting distally has been tried in several patients. This has been done on a case base. No statistical data has been scored or analysed.

Results and Conclusion: By using the distal approach we have found that commencement of the dissection at the most distal extent of the abnormal fascia in the finger allow this to be achieved more safely and rapidly than any other approach. If there is an extreme degree of PIP contracture this method may only be possible after the tight cord(s) have been released at the base of the finger. Otherwise this is now our routine approach.

12:26 Discussion

12:29 **Needle fasciotomy for Dupuytren's contracture**

Mr A Bowey, Mr V Bhalai (Wirral)

Introduction: Dupuytren's contracture is a common condition affecting 25% of men over the age of sixty-five. With less advanced disease or with patient not suitable for a general or regional anaesthetic, needle fasciotomy is the surgical option of choice.

Aim: The aim of this audit is to see whether the Department of Trauma and Orthopaedic Surgery at Wirral University Teaching Hospital NHS Foundation Trust comply with the NICE guidelines.

Methods: All patients who underwent needle fasciotomy for Dupuytren's contracture at Wirral University Teaching Hospital NHS Foundation Trust from December 2008 to November 2010 were identified. The case notes of these patients were reviewed.

Results: In a twenty-three month period nine patients (13 fingers), underwent needle fasciotomy. Six female and 3 male patients. The mean age at the time of surgery was seventy years (61-84 years). Of the thirteen MCPJ contractures, 12 had a full correction. At the PIPJ five of the 8 had a full correction. Of the one contracture affecting the DIPJ, this was fully corrected. None of the patients undergoing a needle fasciotomy had any complications recorded. At a minimum follow-up of four months and a mean follow-up of 14 months, none of our patients have returned to the unit with recurrence of disease.

Conclusions: In our unit needle fasciotomy is safe and effective in correcting deformity. To date we have no complications or recurrence. None of these patients have returned for further surgery. We are compliant with the NICE guidelines.

12:34 Discussion

NOTES

THURSDAY, 31 MARCH**12:37 McCash technique single transverse palmar segmental fasciectomy under local anaesthesia for Dupuytren's disease**

Dr R Finn, Mr G Carlile, Mr A Vaughan, Mr A Al-Shawi (Truro)

Introduction and Aims: Dupuytren's disease is a common hand condition for which a variety of interventional techniques have been described. We aimed to evaluate the McCash single palmar transverse open fasciectomy technique in correcting deformity, restoring hand function and achieving patient satisfaction.

Material and Methods: We present a single surgeon's prospective case series of forty-two patients, with disease primarily affecting the metacarpophalangeal joints treated with open segmental fasciectomy through a single transverse palmar incision. Measurements of deformity and correction were made using a goniometer pre-operatively and at follow-up. Patients were asked to complete a Patient Evaluation Measure (PEM) questionnaire. Case note and statistical analysis were then performed.

Results and Statistics: At a mean of thirteen months follow-up, an average correction of 47.21° was achieved ($p < 0.001$), with 86.5% of patients achieving full correction of contracture. Patient Evaluated Measure scores of hand function were good with an average of 29.78 (range 19 to 58). Nineteen patients were splinted at night for three months, and 23 patients were not splinted; there was no statistical difference in correction achieved ($p = 0.5665$). A low complication rate of 2% was noted with a single superficial wound infection and one patient required revision surgery for recurrence.

Conclusions and Clinical Reference: The outcomes of surgery as assessed by this study indicate good clinical correction with the McCash technique, improved hand function and patient satisfaction as well as a low complication rate. We advocate this technique as a safe and quick procedure which may be performed under local anaesthesia as a day case.

12:42 Discussion

12:45 Five-year results of randomised clinical trial on treatment in Dupuytren's disease: Percutaneous needle fasciotomy versus limited fasciectomy

Mrs A Van Rijssen, Professor P Werker (Zwolle)

Background: Now that the armentarium to treat Dupuytren's disease is increasing, there is a need for comparative studies. Here we present the five-year follow-up results of our randomised controlled study that compared percutaneous needle fasciotomy (PNF) and limited fasciectomy (LF).

Methods: One hundred and eleven patients with 115 affected hands with a minimal passive extension deficit of 30° were randomly assigned to the treatment arms. Follow-up was at one and six weeks, six months, 1, 2, 3, 4 and 5 years post-operatively. Outcome parameters were Total Passive Extension Deficit (TPED), patient-satisfaction, finger flexion and sensibility. We recorded if disease extension occurred during follow-up. Primary end point was recurrence in any treated ray, defined as an increase of TPED of >30°.

Results: After five years, the recurrence rate in the PNF group was significantly higher (84.9%) than that of the LF group (20.9%), $p < 0.001$, and occurred significantly sooner in the PNF group ($p = 0.001$). Higher age at time of treatment diminishes the risk of recurrent disease, $p = 0.005$. We were unable to prove that diathesis characteristics influenced recurrence. Satisfaction was high in both groups, but in the LF group significantly higher than in the PNF group. Nevertheless, many patients (53%) chose to have their recurrence treated by PNF.

Conclusions: PNF is most suitable for elder patients and for those willing to accept the drawback of possible early recurrence and want the benefit of advantages such as fast recovery, low complication rate and minimal invasiveness.

12:55 Discussion

13:00 Lunch and Trade Exhibitions

NOTES

THURSDAY, 31 MARCH**Symposium: State of the Art in Tendon Surgery****Chairman: Mr J S Watson/Mr C A Pailthorpe**

- 14:00 Tendon structure and micro-structure
Professor K Kadler
- 14:25 Why multiple stranded repairs are best
Mr R Savage
- 14:40 Why Tendon sutures are bad
Mr J Wong
- 14:55 Latest flexor tendon outcome data
Mr D Elliot
- 15:15 Panel Discussion
- 15:45 Refreshments and Trade Exhibitions
- Keynote Lectures**
Chairman: Professor T R C Davis/Mr C Duff
- 16:15 Perils in hand surgery
Dr D Lalonde
- 16:45 Discussion
- 16:50 Phalangeal fractures – How I do it
Dr D Lalonde
- 17:00 Phalangeal fractures – How I do it
Mr D J Shewring
- 17:10 Close
- 17:15 Business Meeting (open to Members and Associates only)
- 19:15
for
20:00 Society Buffet Supper – Imperial War Museum North

NOTES

FRIDAY, 1 APRIL

- 07:15 Instructional Course on Collagenase (register at Pfizer stand)
- 08:30 Registration
- Symposium: Your Hand Practice – Present and Future (Part 1)**
Chairman: Mr AN M Fleming/Mr R Eckersley
- 09:00 How I organise my hand practice
Mr D Warwick
- 09:20 Developing independent practice
Mr D M Evans
- 09:40 How I do 30 procedures in a day
Mr L C Bainbridge
- 10:00 Panel Discussion
- 10:20 Refreshments and Trade Exhibitions
- Symposium: Your Hand Practice – Present and Future (Part 2)**
Chairman: Mr J L Hobby/Miss V C Lees
- 10:50 Wide awake hand surgery
Dr D Lalonde
- 11:20 Discussion
- 11:30 Commissioning
Dr R Dudley-Southern MBE, Associate Director (Strategy), North West Specialised Commissioning
- 11:50 Guidelines
Mr AN M Fleming
- 12:00 How to initiate multi-centre clinical trials
Professor D Morton
- 12:20 Panel Discussion
- 12:30 Lunch and Trade Exhibitions
- Free Paper Session 3**
Chairman: Mr I A Trail/Mr L Muir
- 13:30 **An anatomical approach for correction of the extensor lag in free vascularised joint transfers of the proximal interphalangeal joint**
Mr W Lam, Dr N Waughlock, Dr C Hsu, Dr Y Lin (Taiwan)
- Introduction:** Free vascularised joint transfer (VJT) for post-traumatic, complex injuries of the proximal interphalangeal joint (PIPJ) remains a valid option in providing a stable, pain-free and mobile finger. Its popularity is limited, however, by reduced ranges of motion (average 37°) caused predominantly by a persistent extensor lag (average 30°). This prospective study explored different methods of extensor reconstruction based on anatomical findings of toe joints and the residual extensor mechanism in the recipient finger.
- Methods:** Six male patients (mean age 28.7) underwent free VJT for post-traumatic PIPJ injuries of different configurations. During joint harvest, two extensor mechanism types were found: type I with attenuated central slips and type II with robust central slips. When extensor tendons of the recipient finger were adequate, centralisation of the lateral slips to the toe joint was performed (n=3). When the finger extensor tendons were damaged, type I toe joints received a modified Stack procedure (n=1) to reinforce the central slip and type II toe joints simply received a tight extensor repair of both the harvested extensor digitorum longus and brevis (n=2).
- Results:** No vascular or skeletal complications were encountered. At a follow-up period of 13.4 months, the average extensor lag was 17.5° with a mean flexion of 75° thus achieving a TAM of 57.5° at the PIP joint.
- Conclusions:** This preliminary result demonstrates that much improved range of motion can be obtained with less extensor lag if an anatomical approach was adopted that takes into account the residual finger function and toe joint anatomy.

NOTES

FRIDAY, 1 APRIL

13:35 Discussion

13:38 **Ascension pyrolytic carbon proximal interphalangeal joint arthroplasty: Medium term results of a single surgeon series**

Mr P Jesudason, Mr G Nandhara, Mr A McMurtrie, Mr H Naseem, Mr L Muir (Salford)

Background: The National Institute of Clinical Excellence has published guidance on arthroplasty of the small joints of the hand, stating that patients should be prospectively reviewed to assess outcome and potential complications.

Methods: We undertook a prospective review of twenty-three consecutive patients implanted with the Ascension pyrolytic carbon proximal interphalangeal (PIP) joint prosthesis (38 PIP joints; 16 hemi-arthroplasties and 22 total joint replacements), from 2004 to 2010. The mean follow-up was thirty-five months (range 4 -71) and all surgeries were performed by the senior author. Patients were assessed using a 10cm visual analogue score (VAS) of pain, pre- and post-operative arc of motion, a Likert scale of satisfaction, radiographs to assess the implant and a post-operative Michigan Hand Outcome Questionnaire.

Results: 85% of all patients were either satisfied or highly satisfied with their surgery. The mean arc of motion was essentially unchanged after surgery, but the mean VAS pain score decreased from 7.4 to 1.3. Ten patients underwent re-operation (26%); 6 for stiffness (4 underwent tenolysis and 2 manipulations), 1 stitch granuloma and 3 of the hemi-arthroplasties were converted to total joint replacements (one for instability, and two for recurrent pain).

Conclusion: The medium term results are encouraging in terms of pain relief and patient satisfaction, but patients must be counselled that improvement in motion is less predictable.

13:43 Discussion

13:46 **Mid-term results of pyrocarbon resurfacing arthroplasty of the proximal interpalangeal joint**

Mr O Gilleard, Mr J Hutt, Mr N Citron (London)

Introduction: Earlier studies assessing the place for pyrocarbon arthroplasty in the management of PIPJ OA have been promising, although follow-up times have been relatively short. The purpose of this study is to evaluate the medium term outcomes of pyrocarbon PIPJ replacements for osteoarthritis at our institution.

Methods: Between 2001 and 2008, the senior author performed eighteen PIPJ replacements in 15 patients using the Ascension pyrocarbon PIP Total Joint. The latest clinical and radiographic evaluations were performed at a mean of 6.2 yrs, (range 2.1-8.8) post-operatively. Pre-operative and post-operative pain was assessed both at rest and on movement using visual analogue scores. Stability and range of motion at the PIPJ were also recorded. Radiographs were evaluated for signs of prosthesis migration.

Results: There was highly significant improvement in the pain scores ($p < 0.001$), with all patients with surviving implants being completely pain free both at rest and on activity. The mean arc of motion was not significantly improved compared to the pre-operative values (mean AROM=45°, range 0-90°). Radiographs taken at follow-up showed peri-prosthetic erosion and drift in one or both components in ten of the 18 joints.

Conclusion: The results of pyrocarbon arthroplasty for the proximal interphalangeal joint in the medium term are encouraging, with excellent pain relief and a survivorship of 90% at eight years in our series. However, over half the joints had concerning radiographic features. The long term implications of these changes are not certain, as they did not correlate with clinical outcomes.

13:51 Discussion

NOTES

FRIDAY, 1 APRIL

Bell Session

13:54

A study identifying potential donors of 'articular bone graft', for the reconstruction of intra-articular fractures of the proximal interphalangeal joint*Miss T Berrington, Mr T Sillitoe, Dr W Bhatti, Professor D A McGrouther (Manchester)*

Background: Fractures affecting the proximal interphalangeal (PIP) joint frequently result in removal of the volar aspect of the middle phalanx base. Such removal has various presentations, both in terms of the percentage of the middle phalanx base involved, and the number of fracture fragments produced. Although several repair methods are available, there is currently no gold standard capable of repairing all fracture types at this site, with chronic presentations proving particularly difficult to treat. In light of the success of the use of "hemi-hamate" grafts by Hastings et al, this study aimed to explore the remaining carpal bones in the hope of finding additional bone graft donor sites.

Methods: Plaster moulds of the carpal bones were systematically examined for sites with similar contours to the middle phalanx base volar aspect. When a potential donor site was found it was harvested and transplanted onto an artificially fractured middle phalanx.

Results: A potential donor site was located on the most medial point of the dorsal aspect of the trapezium, between the articular surfaces with the scaphoid and trapezoid. A further site on the most superior point of the volar aspect of the capitate that articulates with the base of the third metacarpal was also found.

Conclusion and Implications: Unlike other repair methods, bone grafts are suitable for the treatment of both extensive and chronic presentations. Access difficulty, disease, or injury may preclude the use of the hamate thus necessitating the availability of further donor sites, such as those found in this study.

13:56

A study of planned day case surgery verses inpatient trauma lists for surgical management of distal radial fractures*Miss H Chase, Mr M Kent, Mr P Chapman (Norwich)*

In the United Kingdom, the majority of distal radial fractures requiring fixation are treated on an inpatient trauma list. Patients with a distal radial fracture are potentially suitable for day-case surgery. This study investigated sixty patients with distal radial fractures and compared day case management with the gold standard of inpatient care.

Thirty consecutive patients treated in the day case unit with volar plate fixation were matched for age, ASA grade and fracture classification to the in-patient group (n=30). All inpatients selected satisfied suitable criteria for day case surgery. Data collected included complications, hospital stay, delay to surgery and unplanned readmission. Day case patients underwent telephone questionnaire noting process satisfaction (scored 0-5; 0 low, 5 high), pain control, complications and whether they felt confident with same day discharge.

The mean hospital stay for the general inpatient trauma list was 2.8 days (range 2-7 days). 100% (n=30) of day case patients reported feeling safe following same day discharge and 96% (n=29) felt their pain was adequately controlled at home. The average patient satisfaction score for overall process of day surgery care was 4.5. No difference was noted in complication rates between groups.

An average saving of three bed days was achieved with selective day-case treatment. This represents an estimated saving of £1,200 per patient.

This study demonstrates that utilisation of the day procedure unit for distal radial fracture surgery is safe and satisfactory to the patient. It allows a reduction in hospital stay and confers significant cost savings to the healthcare provider.

13:58

Traction: An old-fashioned but effective way to treat proximal phalanx fractures*Miss L Highton, Miss F Choukairi, Professor D A McGrouther, Mrs F Peck, Miss S Turner (Manchester)*

Introduction: Over the last three years we have treated 26 patients with 29 proximal phalanx fractures by traction splinting and early mobilisation. The group included sixteen female and 10 male patients with a mean age of 41 years (range 17-76). All were closed injuries that affected the phalangeal base (23) or shaft (6) and were transverse (16), comminuted (8), oblique (3) or spiral (2) pattern. Traction was applied for a mean of sixteen days, with treatment and rehabilitation closely monitored by hand therapists.

NOTES

FRIDAY, 1 APRIL

Results: Twenty-one patients had good or excellent results, with total active motion >75% of normal motion. Five patients had less satisfactory ranges of movement. Patients in this group were significantly older (mean 60 years, $p=0.0012$) but there were no other apparent differences in fracture pattern or treatment. On comparison of radiographs taken before and after treatment there was no significant bone shortening ($p=0.99$). There was a significant improvement in fracture angulation, from a mean to 19° dorsal/volar angulation and 9° radial/ulnar angulation before treatment to 5° dorsal/volar angulation ($p=0.0002$) and 2° radial/ulnar angulation ($p=0.0061$) following treatment. One patient required an osteotomy for malrotation and another tenolysis. One patient developed CRPS.

Conclusion: Results following the surgical treatment of phalangeal fractures are often disappointing. We have demonstrated that good outcomes may be achieved through traction and early mobilisation. Further studies are required to determine which patients are suitable for this treatment and to directly compare the outcomes following traction splinting and surgery in the management of proximal phalanx fractures.

14:00

A new predictor of instability after manipulation of distal radial fractures: Restoration of the volar cortex

Mr A Phillips, Mr A Al-Shawi, Mr T Scott (Exeter)

Introduction: Whether to operate or not on distal radial fractures still vexes the majority of orthopaedic surgeons. The practice varies hugely from surgeon to surgeon and region to region, but almost all fractures are manipulated either as first aid or definitive treatment. We sought to add a new predictor of instability, restoration of the volar cortex (VC) during manipulation, to the evidence base to help clarify management of these often difficult fractures.

Methods: We audited eighty-eight consecutive distal radial fractures that had been manipulated by A&E staff and analysed what factors predicted the need for further surgery based on current evidence.

Results and Statistics: The most significant predictor of instability and hence further surgery was not anatomic restoring the volar cortex during the manipulation ($p=0.008$). Other significant factors were increasing age ($p=0.44$) and fracture of the ulna styloid ($p=0.027$). If the VC was restored or remained intact during the manipulation only 38% required further surgery. If the VC was displaced or not restored 65% required further surgery. Thirty patients had no dorsal translation at presentation. Of these, five patients' VC was displaced during the manipulation, 80% of whom required further surgery. If the VC was not disturbed only 28% required further surgery.

Conclusions: Restoration or maintenance of the volar cortex during manipulation of distal radial fractures offers patients the best chance of avoiding the need for further surgery. This predictor should be taken into account in the decision making process for these fractures.

14:02

Investigating occult fractures of the scaphoid - Is there a need for a paradigm shift?

Mr S Shetty, Mr S Sidharthan, Mr J Jacob, Mr R Balasundaram (Rhyl)

Introduction: Most patients with post traumatic painful wrists and negative radiographs are followed-up with a repeat radiograph in ten -14 days. If the radiographs are inconclusive then further imaging is done. However, this traditional approach results in a vast majority of patients being unnecessarily immobilised for an unspecified period leading to loss of productivity and income to the patient and community. A number of studies have highlighted the use of early CT or MRI scans to identify these fractures.

Aim: To evaluate our current practice in managing patients with suspected fractures of the scaphoid.

Patients and Methods: Retrospective audit. Study period: January-August 2008. Fifty consecutive patients who were investigated for occult fractures of the scaphoid were included.

Results: 92% of patients had a repeat radiograph in the fracture clinic. 84% of the patients had their wrists immobilised in a cast while awaiting further imaging. Only 6% had confirmed fracture of the scaphoid, all of which went on to heal uneventfully. 76% of patients with negative scans had their wrists immobilised for an average period of 30.63 days.

NOTES

FRIDAY, 1 APRIL

Conclusion: *It is time we rethink this dogmatic approach to patients presenting with painful wrists following an injury. The paradigm of review and re X-ray has been shown to be ineffective and a large number of patients still undergo needless immobilisation. Instead, we recommend that this group of patients with a painful wrist following an injury should be referred early to an appropriate clinician and earlier recourse to MRI is advocated to confirm the diagnosis.*

14:04

Early computed tomography for suspected occult scaphoid fractures*Mr J Stevenson, Mr L Murugesan, Mr D Morley, Mr S Srivastava, Mr I Bhoora (Stafford)*

Introduction: *Up to 16% of scaphoid fractures are radiologically occult. Failure to diagnose scaphoid fractures may lead to delayed union, nonunion or avascular necrosis. Fractures may take weeks to be excluded and many patients are unnecessarily immobilised increasing work absence, clinical reviews and cost. The use of CT early in the management of suspected occult scaphoid fractures has been evaluated.*

Methods: *The radiology and clinical notes of all patients who have had scaphoid CT scans over the preceding three years were retrospectively reviewed. Eighty-four patients that had CT scans within 14 days from injury were identified.*

Results: *64% of CTs excluded fracture (N=54) and these patients were mobilised promptly and reviewed within six weeks. No patients returned with any complications, such as carpal instability, from this management strategy. Mean number of clinic appointments for this group was 2.34 (range 2-6). 36% of CTs were abnormal (n=30). 7% revealed occult scaphoid fractures; 18% revealed occult carpal fractures of the triquetrum, capitate and lunate respectively and 5% distal radius fractures. All patients diagnosed with fractures were successfully managed with plaster immobilisation with one case of regional pain syndrome.*

Conclusions: *Early CT immediately alters therapeutic decision making in suspected occult fractures preventing unnecessary immobilisation. Early CT also reduces clinic attendances for clinical and radiological review without increase in cost.*

14:06

Clinical and radiological outcomes of the Acu-loc™ volar plate for fractures of the distal radius*Mr R Owen, Mr J Casaletto, Mr D Brown (Liverpool)*

Introduction: First described by Abraham Colles, fractures of the distal radius are one of the most common fracture types encountered. The management of these fractures has changed significantly since early reports.

Patients: Eighty-eight patients who had fixation of a wrist fracture using the Acu-loc™ plate were identified (54 female, 34 male), including six patients with bilateral injuries, giving a total of 94 fractures. The mean age of patients included was 53.5 (range 21-84). Majority of patients were right hand dominant (89%) with most fractures being to the left wrist (60%).

Clinical Outcomes: Mean follow-up time for clinical outcomes was twenty-one months post-operatively. QuickDASH score mean was 8.94 (SD 15.7). VAS score mean was 1.3. Complications in this series were carpal tunnel syndrome 4 (4%), CRPS 1 (1%), wound infection 3 (3%), non-union 1 (1%), flexor tendon irritation or rupture 4 (4%).

Radiological Outcome: The mean change in the measured radiological parameters during the follow-up period was 0.28mm (-2 to 11) for radial length, 0 (-8.7 to 11.5) for radial inclination and 2.14 (-15 to 21.7) for palmar tilt.

Conclusion: The results of this study support that volar locking plates provide a stable method of fixation of fractures of the distal radius allowing early mobilisation and favourable outcomes. The Acu-loc™ plate is one such device which has been validated in this study to compare very well with other volar locking systems.

14:11

Discussion

NOTES

FRIDAY, 1 APRIL

14:14

Open versus closed fixation of metacarpal fractures - Infection rate in a busy hand surgery unit

Mr A Allouni, Miss A Murray, Mr S Southern, Mr S Majumder (Wakefield)

Introduction and Aims: Complication rate of open vs closed fixation for metacarpal fractures has rarely been studied, despite being such commonly performed procedures. Botte et al (1992) showed an 18% complication rate for k-wire fixation compared with Stahl et al (2001) who reported 15.2%. Fusetti (2002) reported a 33% complication rate for ORIF metacarpal fractures. Our unit treats operatively an average of four hundred and seventy patients with hand fractures yearly. We present our unit's infection complication rate for these two techniques, taking a cohort of metacarpal fracture patients.

Methods: Data was obtained retrospectively from our hand therapy unit patients' notes. We reviewed all metacarpal fractures, which were treated operatively over a six-month period (January-June 2009), with regard to fracture site, patient age, past medical history, and infection complications.

Results: Out of one hundred and sixty-seven operatively fixed hand fracture cases during this period, 112 (67%) were metacarpal fractures (open and closed) while the rest 55 (33%) were phalangeal fractures. Of the metacarpal fractures sixty-four (57%) were managed with ORIF. The rest of forty-eight (43%) were managed with k-wires. Seven (6.25%) patients had infection. All infections were seen following k-wire fixation of closed metacarpal fractures 14.6% (n=7, of 48). Infection complication rate following ORIF was 0%.

	Metacarpal - 112	Phalangeal - 55
K-wire	48 (43%)	54 (98.2%)
ORIF	64 (57%)	1 (1.8%)
Complications	7 (6.25%)	3 (5.45%)

Conclusions: In our study we found that rate of infection following k-wire fixation was far higher than ORIF fixation of metacarpal fractures (14.6% vs 0%).

14:19

Discussion

14:22

A descriptive study of MRI findings in adults with wrist sprains with normal X-rays

Dr T H Bergh, Mr T Lindau, Dr L Soldal, Dr S Bernardshaw, Dr K Steen, Dr M Behzadi, Associate Professor C Brudvik (Bergen)

Aims: Wrist injuries with negative X-rays are usually diagnosed as acute wrist sprain. The aim of this study was to explore the pathoanatomical diagnosis using acute MRI.

Material and Methods: A prospective MRI study with patients aged eighteen to 49 years, attending Bergen AED, Norway after having sustained an acute wrist trauma. Acute X-rays excluded fractures or dislocations. MRI was done within a median of two days (range 0-28 days) after the trauma.

Results: A total of one hundred and fifty-three acute MRIs were done; 38 were normal. 75% of all patients had two hundred and forty-nine pathological MRI findings including 52 fractures, 50 bone bruises, 11 TFCC injuries and four scapholunate ligament lesions. The identified fractures were located in the distal radius (n=14), scaphoid (n=13), base of the metacarpal bones (n=13), triquetrum (n=6), capitate (n=3), ulna (n=2) and trapezoid (n=1). Bone bruises (n=50) were found in all eight carpal bones, in the radius, ulna and metacarpal bones. Ten patients had traumatic tendon lesions. Other soft tissue pathology included synovitis (n=53), various ganglions (n=25) and thenar contusions (n=5).

Conclusions: Acute wrist sprain is an inaccurate diagnosis. MRI of patients with acute wrist trauma and negative X-ray had pathological findings in 75% of all patients. We found that the conservative treatment for these patients improved with a precise diagnosis. We recommend that MRI should be considered as an early investigation, especially if the wrist pain does not settle in two weeks after a wrist sprain.

14:32

Discussion

NOTES

FRIDAY, 1 APRIL

14:37 **Short to medium term results using the re-motion total wrist replacement for rheumatoid arthritis**
Mr A Bidwai, Mrs F Cashin, Mrs A Richardson, Mr D Brown (Liverpool)

Introduction: We present the clinical outcome of fourteen patients (sixteen replacements) who underwent Re-motion Total Wrist Replacement (TWR) for the treatment of rheumatoid arthritis of the wrist. This audit is in compliance with NICE IPG 271, which obligates orthopaedic surgeons who offer TWR to review patient outcome.

Methods: Patients who had previously undergone TWR were invited for clinical and radiographic assessment to a specifically created clinic. The NICE audit tool designed to support clinicians in data collection was modified for local use.

Results: Sixteen patients were available for follow-up, up to five years after index surgery. Mean pain and satisfaction scores (1-10) were 3.67 and 6.67 respectively. Flexion ranged from 10° to 60° and extension 0° to 30°. Two patients who were TNF-a medication required surgical intervention for wound breakdown, including one patient who required a radial forearm flap for skin coverage. This patient had a poorer outcome on average compared to the other patients. No patients required revision surgery or conversion to fusion. One patient (2 wrists) had radiographic lysis around the central carpal peg. This patient was asymptomatic and there was no evidence of progression.

Conclusions: In this small case series with short to medium results all except one patient reported good pain relief, useful range of movement and an improvement in terms of function. The question of efficacy of TWR compared to fusion in the long-term remains unanswered. Other centres using the same implant are encouraged to pool similar data to provide more meaningful outcome data.

14:42 Discussion

14:45 **Is the dart thrower's motion of the human wrist of functional importance?**
Mr G Brigstocke, Mr A Hearnden, Dr C Holt, Dr G Whatling (Guildford)

Introduction: The dart thrower's motion (DTM) occurs at the mid-carpal joint and is an oblique plane of global wrist movement from radial extension to ulnar flexion. Wrist anatomy permits stable controlled motion along the DTM plane with minimal motion of the proximal carpal row. The study aim was to quantify the use of the DTM during activities of daily living (ADLs).

Methods: Global wrist motion of ten right hand dominant male subjects was recorded at the Cardiff School of Engineering Motion Analysis Laboratory. Eight Pro-reflex MCU digital infra-red cameras (Qualisys, Sweden) were used to record the movement of retro-reflective marker clusters attached to the subject's hand and forearm. 6° of freedom calculations were performed to quantify wrist kinematics. The plane of global wrist motion during the ADLs were quantified and compared to the DTM plane.

Results: The mean DTM plane was defined as 44.7±12° to the sagittal plane of the forearm. Global wrist motion approximated the DTM plane when hammering a nail (42.4°), throwing a ball (34.2°), drinking from a glass (55.6°), pouring from a jug (38.2°) and twisting off and on the lid of a jar (34.2°). The DTM plane was not utilised during hair combing or whilst undoing and doing-up buttons.

Conclusions: The DTM is the plane of global wrist motion utilised during most ADLs. This study supports the hypothesis that fusion of the radio-carpal joint instead of the mid-carpal joint during selective partial fusions of the wrist will allow better wrist function during most ADLs.

14:50 Discussion

14:53 **Clinical scaphoid score (CSS) in wrist injury with normal X-ray: A comparison with scaphoid pathology confirmed by MRI**
Associate Professor C Brudvik, Dr T H Bergh, Dr L Soldal, Dr S Bernardshaw, Dr K Steen, Dr M Behzadi, Mr T Lindau (Bergen)

Aims: Evaluate three commonly used tests to identify scaphoid pathology after wrist trauma and compare them with MRI pathology despite normal initial X-rays.

NOTES

FRIDAY, 1 APRIL

Material and Methods: Patients with traumatic wrist pain attending Bergen AED, Norway were included if initial X-rays were normal. They were examined with three clinical scaphoid tests; pain in the anatomical snuffbox (3 points), on the scaphoid tubercle (2 points) and when axially compressing the thumb (1 point). The clinical scaphoid score (CSS) is a summary of these points and was compared with MRI pathology (scaphoid fractures and bone bruise). MRI was done within a median of two days (range 0-28 days) after injury.

Results: We included one hundred and fifty-three patients; 13 had scaphoid fracture and eight scaphoid bone bruise. A CSS of three points or more had a sensitivity of 85%, specificity of 44%, positive predictive value of 13% and negative predictive value of 97% for scaphoid fractures. When adding bone bruise to fracture of the scaphoid, the positive predictive value increased to 24%. The sensitivity in examinations done by experienced AED-doctors (100%, n=77) were significantly higher than by junior doctors (71%, n=76).

Conclusion: Clinical tests do not identify scaphoid pathology well in patients with negative X-ray. Diagnostic sensitivity increased with more experienced AED doctors. In patients with CSS less than three points, a negative predictive value of 97% indicates that the risk of scaphoid pathology is low. In patients with CSS of three points or more, the threshold for further MRI should be lower than in present practice.

14:58 Discussion

15:01 Outcome of fracture fixation using volar locking plates of the distal radius

Mr D E Giebal, Mr J Stevenson, Mr L Murugesan, Mr G Pavlou, Mr I Bhoora (Stafford)

Objective: Determine complication rates following the use of volar locking plates in distal radius fractures, to identify any potential improvements, and to describe functional outcomes following surgery.

Materials and Method: We performed a retrospective data collection on a series of one hundred and seventy-seven patients (178 wrists) admitted for internal fixation of distal radius fractures between January 2007 and December 2009. Twenty-five patients were excluded. One hundred and sixteen female and 38 male with a mean age 54, and a median age of 57 (18-84) were available for follow-up. Case notes were reviewed along with radiographs and functional assessments were recorded using the Disabilities of Arm, Shoulder and Hand (DASH) scoring system and the Patient Rated Wrist Evaluation (PRWE) score.

Results: Total 28% complication rate. Thirteen patients (8.4%) had removal of plate or are listed for removal. One patient had a fasciotomy following compartment syndrome, one patient had revision surgery, one deep wound infection requiring removal, two superficial wound infections and one patient with post-op DVT. Seven (4.5%) had inadequate reduction following surgery, and 11 (7.14%) were complicated by further collapse following reduction. Mean DASH scores were 10.3 and did not correlate with X-ray appearances post reduction or with fracture classification.

Conclusion: In our case series, complications following surgery remain high. Fixation with volar locking plate seems to be suitable for AO B type fractures of the distal radius. Careful consideration of the risks of surgery, with operating preferably under the supervision of upper limb consultants for the other AO fracture configurations and dorsally displaced fractures.

15:11 Discussion

NOTES

FRIDAY, 1 APRIL

Bell Session

15:16

A prospective audit of patient satisfaction with the component parts of carpal tunnel decompression
Mr A Bidwai, Mr H Benjamin-Laing, Dr S Iqbal, Miss D Shaw, Mr W Jones, Mr D Brown (Liverpool)

Introduction: The outcome of carpal tunnel decompression is well documented in the medical literature. It is not, however, well documented as to the patient satisfaction of the individual parts of the procedure. The aim of this study was to determine the level of patient satisfaction with these individual steps in order to identify individual aspects where improvements to the service could be made.

Methods: Fifty patients were recruited into the study upon presentation for surgery. A questionnaire was completed immediately post-operatively. Areas of patient satisfaction measured included, tolerance of tourniquet and local anaesthetic, subjective pain scores and overall satisfaction. A subset of these patients was followed-up to discharge in order to determine satisfaction with suture removal.

Results: Satisfaction levels were very high with most aspects of the patient journey. In terms of the procedure, the tourniquet and local anaesthetic were the least well tolerated, although not in all patients. Interestingly lack of tolerance of these steps showed no significant relationship to the overall patient experience. Suture removal is tolerated well by patients. Almost every patient would recommend the procedure to a friend or relative.

Conclusions: In this study we have been able to demonstrate that even when patients poorly tolerate individual component parts of carpal tunnel decompression surgery, this does not result in a poor overall patient experience of the procedure. This then questions the benefit of striving to develop strategies to reduce patient intolerance to the component parts, for example, performing surgery without a tourniquet or warming the anaesthetic.

15:18

Total wrist arthrodesis using a dorsal fusion plate - Should the 3rd carpometacarpal joint be fused?
Miss H Chase, Mr T Halsey, Mr P Chapman, Mr A Chojnowski (Norwich)

The decision whether to fuse the third carpometacarpal joint (CMCJ) during wrist arthrodesis is controversial. Degenerative change in unfused CMCJs can occur but non-union following attempted fusion is recognised as a potential source of ongoing pain.

In this single centre, two surgeons' retrospective case series we compared the outcome of patients who underwent wrist fusion with and without CMCJ fusion at a minimum of six months follow-up for osteoarthritis. The AO pre-contoured plate was applied dorsally, either with or without attempted CMCJ fusion according to surgeon's preference. The requirement of further surgery and any complications were recorded. Patients with rheumatoid arthritis were excluded.

Twenty-five patients identified from theatre records over a three-year period. Sixteen patients underwent arthrodesis with CMCJ fusion and nine patients without fusion. Two of the nine not fused CMCJ were revised due to a symptomatic CMCJ. All fusions in the attempted fusion group were radiologically and clinically confirmed. Four of the nine patients with unfused 3rd CMCJ underwent removal of symptomatic metalwork compared to two of the 16 patients with CMCJ fusion. No other complications were noted in either group.

In this small, non randomised sample, we found that the risk of further surgery is increased by choosing not to fuse the 3rd CMCJ during wrist fusion.

15:20

Treatment of distal radial fractures with the DVRA plate - The early Bristol experience
Mr J Loveridge, Dr C Gee, Mr N Ahearn, Mr D Pearson, Mr S Sivaloganathan, Mr R Bhatia (Bristol)

Aim: The aim of our study was to assess how adequately reduction was reproduced and maintained with the DVRA volar locking plate as well as assessing function and post-operative range of motion.

NOTES

FRIDAY, 1 APRIL

Method: We looked at a consecutive series of one hundred and eleven patients treated with the DVRA plate at our institution from 2007-2010. The pre-operative, intra-operative and post-operative films were reviewed. The Frykman classification was recorded. The sagittal tilt, radial inclination and radial length were measured on initial post operative X-ray and compared with the last post-operative X-rays. The last recorded range of motion at follow-up and a functional assessment using the DASH score was recorded.

Results: A mean intra-operative sagittal tilt of 9.04° was achieved with a mean sagittal tilt of 6.8° at final follow-up. A mean intra-operative radial inclination of 22.05° was achieved with a mean radial inclination at final follow-up of 22.12°. A mean intra-operative radial length of 12.2mm was measured and a mean radial length at last follow-up of 12.01mm. The mean extension was 46.8°, flexion 48.3°, pronation 77.4°, supination 74.8°, radial deviation 15.3° and the ulnar deviation 19°.

Conclusion: The DVRA plate achieved adequate reduction of the distal radius radial length and radial inclination but showed a 3° loss of sagittal tilt at last post-operative X-rays.

15:22

Do patients really do better after Sauve-Kapandji's procedure compared to Darrach's? A systematic review

Mr D Nikkhah, Mr J Rodrigues, Mr P Loughenbury, Mr W DeJager (Bradford)

Introduction: Different operative options exist for treating distal radioulnar joint (DRUJ) dysfunction. Sauve-Kapandji's (SK) procedure has become increasingly popular compared to the more traditional Darrach's procedure, with instability, ulnar carpal shift (UCS) and cosmetic complaints cited as complications of the latter. We present a systematic review of studies comparing the two.

Methods: OvidMEDLINE and EMBASE were searched for the terms "Darrach" or "Sauve-Kapandji". All articles in English with an abstract available were identified. Abstracts were screened to select those comparing Darrach's and SK.

Results: Out of two hundred and fourteen articles found, only five comparative studies were identified. All were retrospective. Three described treatment of rheumatoid arthritis (RA), one osteoarthritis (OA) and one post-Colles fracture. One study only considered radiological outcomes; all others considered clinical and radiological outcomes. Two of the RA studies suggested that UCS was more common after Darrach's procedure, though no comparative statistics were performed to confirm this. However, as the Darrach's cohort was small in one of the studies, bias may have arisen from this limited and infrequent surgical experience. The radiological study found no statistical difference in UCS between groups. When statistical analysis was performed on the data in the OA study, no significant difference in instability between groups was demonstrated. The post-Colles study demonstrated no difference between groups.

Discussion and Conclusion: There is a marked paucity of evidence comparing outcomes between these procedures. Given the increased technical difficulty and invasiveness of SK procedure, is it time for a large prospective comparative study to identify the role of each operation?

15:24

Corrective distal radius osteotomy using fixed angle volar locking plate

Dr S Opel, Mr S Konan, Dr A Das, Mr E Sorene (London)

Introduction: Post traumatic distal radius deformity may cause severe morbidity with restriction of wrist mobility and function. Corrective osteotomy is often necessary to realign the functional axis of the wrist to correct symptomatic malunion. The aim of this study was to review the mid-term results of a single surgeon's series of distal radius corrective osteotomies following distal radius fracture malunion using a fixed angle volar locking plate.

Methods: Seventeen patients underwent corrective osteotomy using a fixed angle volar locking plate for post-traumatic distal radius malunion. No plaster of Paris mobilisation or structural bone graft was used in any case. The indication for the operation was pain and functional limitation. Fourteen were women and three were men, with an average age of 55 years. Outcome was assessed using radiological and clinical confirmation of union, patient satisfaction and the DASH questionnaire post-operatively.

NOTES

FRIDAY, 1 APRIL

Results: At mid-term follow-up, no complications were noted in any cases. Radiological union was confirmed in all cases at three months. Patients noticed an improvement in their wrist function. This was objectively confirmed by an average post-operative DASH score of 13.48. Wrist alignment significantly improved, as demonstrated by measurements on plain radiographs.

Conclusion: At mid-term follow-up, corrective osteotomy of the distal radius for symptomatic post traumatic malunion has excellent functional outcome.

15:26

Diagnostic accuracy of clinical examination and magnetic resonance imaging for common articular wrist pathology

Miss J Ruston, Mr S Konan, Miss E Rubinraut, Mr E Sorene (London)

Aims: Our aim was to compare the diagnostic accuracy of clinical examination and magnetic resonance imaging (MRI) for intra articular wrist pathology, using wrist arthroscopy as the gold standard.

Methodology: Patients undergoing wrist arthroscopy for triangular fibrocartilage complex (TFCC), scapholunate (S-L) and lunotriquetral (L-T) ligament injury were selected for the study. There were sixty-six patients with ages ranging from 10 to 68 years. All patients had clinical examination and arthroscopy, while thirty-eight had also undergone an MRI scan.

Results: Using arthroscopy as gold standard, clinical examination of the wrist was noted to have sensitivity of 63.9%, specificity of 42.4%, PPV of 54.8%, NPV of 56% and accuracy of 56.1%. The corresponding values for MRI were 47.6%, 64.7%, 62.5%, 50% and 55.3% respectively. Of the thirty-eight patients who had both clinical examination and MRI before arthroscopy, 17 of the patients had consistent findings across examination and MRI (44.7%). The accuracies of clinical examination for detecting specific pathology were 72.7% (TFCC), 78.8% (L-T) and 60.6% (S-L). For MRI scans the accuracies were 71.1%, 84.2% and 65.8% respectively.

Conclusion: There is no statistically significant difference in the accuracy of MRI and clinical examination for diagnosis of common wrist pathology. However, MRI was significantly more specific than examination. Clinical examination and MRI were not significantly different for detection of the individual pathologies, though examination detected TFCC injuries more accurately and MRI detected better the L-T and S-L injuries.

15:28

Wrist denervation in isolation: A prospective outcome study with patient selection by wrist blockade

Mr P Storey, Mr T Lindau, Ms V Jansen, Ms S Woodbridge, Mr C Bainbridge, Professor F Burke (Barnsley)

Surgical wrist denervation involves division of the anterior and posterior interosseous nerves and articular branches of the superficial radial nerve. In this outcome study, thirty-seven patients were individually assessed and deemed suitable for denervation surgery due to appreciable symptom resolution following a local anaesthetic wrist block. At a mean of eighteen months following denervation surgery, median activity pain scores had decreased by 60% ($p < 0.001$) from initial assessment levels, and more than three quarters (30 / 37) of patients reported continued improvement in their activity pain ($p < 0.001$). More than two thirds of patients had a satisfaction VAS of greater than 50, with less post-operative resting pain and a greater reduction in post-operative activity pain as the important predictors of patient satisfaction. We have found this procedure useful in ameliorating symptoms for some patients who would conventionally have required partial or total wrist fusions with greater residual functional limitation.

15:30

Reproducibility of Watson and Ballet classification for scapholunate advanced collapse (SLAC) of wrist

Mr K Vishwanathan, Mr A Shyam Kumar, Mr A Hearnden, Mr S Talwalkar, Mr M Hayton, Professor R Murali, Mr IA Trail (Chester/Wrightington)

Introduction: Scapholunate advanced collapse (SLAC) is the commonest pattern of degenerative arthritis of the wrist representing 72% of the total cases. Though Watson and Ballet classification has been described in 1984 and is widely used, there has been no study evaluating reliability and reproducibility of this classification. Aim of this study is to quantify interobserver and intraobserver agreement on Watson and Ballet classification.

NOTES

FRIDAY, 1 APRIL

Materials and Methods: Anteroposterior radiographs of the wrist of forty-three cases with SLAC were graded on two separate occasions by 4 orthopaedic consultants specialising in wrist and hand surgery. The assessors were blinded to all patient identifiable information. Cases were identified from theatre logbooks. All surgeons graded the radiographs independently. Intraobserver agreement was tested by asking the assessors to grade the radiographs after 2-4 weeks. The order of radiographs was reversed during re-assessment. The initial set of readings was selected to estimate interobserver agreement. Kappa values and 95% confidence interval of the kappa value were estimated using STATdirect software. Landis and Koch criteria was used to assess level of agreement.

Results: The interobserver agreement was fair (kappa value = 0.26; 95% CI [0.18, 0.34]) and the overall intraobserver agreement was fair as well (kappa value = 0.35; 95% CI [0.15, 0.55]).

Conclusion: The classification system has limited value due to low interobserver and intraobserver agreement. This low agreement in the classification of this condition could lead to different treatments and comparison of treatment modalities for research purposes based on the present classification is questionable.

15:32

Interobserver and intraobserver agreement of classification for scaphoid nonunion advanced collapse (SNAC) of wrist

Mr K Vishwanathan, Mr A Shyam Kumar, Mr A Hearnden, Mr S Talwalkar, Mr M Hayton, Professor R Murali, Mr IA Trail (Chester/Wrightington)

Introduction: Chronic scaphoid nonunion leads to a predicted pattern of arthritis of the wrist. This pattern of arthritis was termed scaphoid nonunion advanced collapse (SNAC) by Krakauer et al. Aim of this study is to quantify interobserver and intraobserver agreement of the most commonly used radiographic classification.

Materials and Methods: Anteroposterior radiographs of the wrist of forty-nine cases with SNAC were graded on two separate occasions by four orthopaedic consultants specialising in wrist and hand surgery. The assessors were blinded to all patient identifiable information. Cases were identified from theatre logbooks. All surgeons graded the radiographs independently. Intraobserver agreement was tested by asking the assessors to grade the radiographs after 2-4 weeks. The order of radiographs was reversed during re-assessment. The initial set of readings was selected to estimate interobserver agreement. Kappa values and 95% confidence interval of the kappa value were estimated using STATdirect software. Landis and Koch criteria was used to assess level of agreement. Kappa value of more than 0.70 is indicator of satisfactory level of interobserver and intraobserver agreement of classification system.

Results: The interobserver agreement was slight (kappa value = 0.08; 95% CI [0.01, 0.15]) whereas the overall intraobserver agreement was fair (kappa value = 0.27; 95% CI [0.08, 0.46]).

Conclusion: This classification system has limited value due to low interobserver and intraobserver agreement. This low agreement in the classification of SNAC wrist could lead to different treatments and comparison of treatment modalities for research purposes based on the present classification is questionable.

15:34

Are intra-operative radiographs useful in small joint arthrodesis in the hand?

Mr N Riley, Mr P D Burge (Oxford)

We examined the post-operative radiographs of one hundred and fifty-five small joint arthrodeses performed both with and without intra-operative radiographs to determine if the quality of fixation was, or could have been, enhanced by intra-operative radiographs. The most recent post-operative radiograph was scored for alignment and hardware position on a three-point scale (good, suboptimal and poor).

In eighty-six distal joint fusions performed with intramedullary screws, intra-operative radiographs had been taken in 22/68 fusions scored as good, in 12/14 scored as suboptimal and in 3/4 scored as poor. Suboptimal and poor features included lateral displacement on the PA view, distraction, breach of the dorsal cortex of the distal phalanx and prominence of the screw in the pulp. Most resulted from technical errors.

NOTES

FRIDAY, 1 APRIL

Optimum alignment and fixation can be achieved in distal joint arthrodesis without intra-operative radiographs if the technique is correct. Indications for intra-operative radiographs include poor bone stock and regarding the alignment or fixation on visual inspection. Screw length and calibre may be altered but other errors may not be correctable, or avoided by taking intra-operative radiographs.

In sixty-nine tension band arthrodeses of PIP and thumb MP joints, intra-operative radiographs had been taken in 9/42 fusions scored as good, in 1/23 scored as suboptimal and in 1/4 scored as poor. Incorrect pin length was the most frequent error. Tension band arthrodesis does require intra-operative radiographs unless the surgeon is confident of pin position and length.

15:36 **Trapeziumectomy with pyrocarbon interposition arthroplasty for the treatment of trapeziometacarpal osteoarthritis**

Mr S Sawalha, Mr J Giddie, Mr J Jones (Peterborough)

Introduction: Trapeziometacarpal joint (TMJ) osteoarthritis (OA) is a common condition. Operative treatment options range from trapeziumectomy with or without tendon interposition to joint replacement. The use of a pyrocarbon spacer to maintain the height of the thumb after trapeziumectomy has gained popularity recently. We report our experience of trapeziumectomy and pyrocarbon (Pi2) spacer interposition for the treatment of TMJ OA.

Patients and Methods: Twenty (20) trapeziumectomies with Pi2 spacer insertion were performed in 18 patients over a two-year period. Pre and post-operative radiographs were reviewed. Eaton TMJ OA grade, position of spacer relative to thumb metacarpal and scaphoid-metacarpal distance was recorded. Complications and re-operations were recorded. Patients were followed-up at an average of seventeen months (range 5-27 months) post-operatively.

Results: Six (6) Pi2 spacers (30%) dislocated or subluxed post-operatively required removal. A further spacer subluxed volarly but the patient remained asymptomatic and the implant was not removed. The scaphoid-metacarpal distance was maintained in all cases even after the implant had been removed.

Discussion: Most patients reported good hand function post-operatively even after the implant was removed. The study confirms the earlier reports of a high dislocation rate of this spacer indicating that it is an unstable implant. The use of the Pi2 spacer has ceased in this unit.

15:38 **A review of outcomes of modified soft tissue reconstruction for rheumatoid metacarpophalangeal joints (MCPJ) Swanson arthroplasty**

Mr U Abdulkadir, Mr R Savage (Newport)

Introduction: Soft tissue reconstruction in MCPJ Swanson arthroplasty may include: extensor hood reefing, radial side volar ligament transfer, crossed intrinsic transfer or extensor loop procedure (Swanson 1972, Mannerfelt and Andersson 1975, Nicolle 1979, Stothard et al. 1991). Our technique uses extensor hood overlap and oblique repair which transmits extensor tendon tension to the radial side intrinsic tendon and modified bone resection.

Method: Surgery was performed by the senior author. Patients were assessed by PEM score, deformity, range of movement, hand grip and pinch strength.

Results: There were thirty-eight patients with 53 operated hands at average follow-up of 5.3 years. There was recurrent ulnar deviation in six hands and over-correction in three fingers.

Results	Pre-op (Xray)	Post-op (clinical)
MCPJ extensor lag	40° (10 - 70)	15° (00 - 30)
MCPJ flexion	80° (40 - 90)	55° (20 - 80)
MCPJ functional ROM	40° (10 - 60)	50° (10 - 80)
Finger ulnar deviation	30° (10 - 55)	10° (05 - 15)

NOTES

FRIDAY, 1 APRIL

Finger ulnar deviation on Xray	Pre-op	Post-op
Index	30° (0 - 50)	8° (0 - 15)
Middle	30° (0 - 55)	15° only one case
Ring	25° (0 - 45)	10° only one case
Little	25° (0 - 45)	10° (0 - 20)

Post-op radiographs were assessed for dislocation (0), subluxation (2), fracture (0) and osteolysis (4).

Conclusion: Our review shows this technique of soft tissue reconstruction is comparable to results in the literature for recurrence of deformity and functional range of movement with high patient satisfaction. We believe the multi-strand oblique sagittal band repair is easier to perform than other methods.

15:43 Discussion

15:46 **DIP joint replacement - Outcome with and without division of the extensor tendon**
Miss C J Zweifel, Mr A Sierakowski, Mrs M Sirotakova, Mr D Elliot (Zürich/Chelmsford)

Purpose: Degenerative changes to the distal interphalangeal joints can be both disabling and disfiguring. Arthrodesis is still considered by most surgeons to be the gold standard of operative treatment, although many finer functions of the hand rely on the rapid movement of these joints through a small range of motion. The standard technique of DIP joint replacement necessitates transection of the extensor tendon, thus necessitating 6-8 week of joint immobilisation post-operatively. This paper introduces a new technique of DIP joint replacement keeping the extensor tendon intact to allow immediate post-operative mobilisation and compares the outcomes of the two techniques.

Methods: Twenty-nine consecutive patients who had undergone 39 DIPJ arthroplasties with division of the extensor tendon (Group 1) were compared to 61 consecutive patients who had the extensor tendon spared in 95 DIP joint replacements (Group 2). The average age was fifty-nine years in both groups. The implants had been in situ for a mean period of fifty-seven months in Group 1 and 27 months in Group 2 at final assessment.

Results: The mean post-operative range of motion of the DIP joint was 39.9° in Group 1 and 38.4° in Group 2. All patients reported that their pre-operative pain was effectively eliminated by the procedure. One joint in Group 2 was unstable.

Conclusions: Compared with arthrodesis, silicone interpositional arthroplasty offers an advantage of retained motion while preserving pinch stability. Similar results can be achieved without dividing the extensor tendon, thereby avoiding the need for a lengthy period of immobilisation post-operatively.

15:51 Discussion

15:55 Closing Remarks

16:00 Close of Meeting

NOTES

POSTERS

1. **A biomechanical comparison of human, porcine and ovine deep flexor tendons: What is the ideal model for laboratory studies?**

Mr R Savage, Mr T Peltz, Mr R Haddad, Mr P Scougall, Mr B Walsh (Sydney)

Introduction: Cheese-wiring of suture through tendon is a major factor in failure of tendon repairs. It is possible that different species have different physical properties related to tendon morphology and that in laboratory tests this could influence tendon repair strength irrespective of the tendon suture method. We conducted a biomechanical study to determine the animal model most similar to human tendon for cheese-wiring; and we compared the histological microstructure.

Method: Deep flexor tendons were harvested from adult pig hind limbs (n=12), adult sheep hind limbs (n=12), and fresh frozen human cadaveric hands (n=12). At a standardised point in zone II a 3/0 Ticon suture was used to take a 2mm bite across the tendon, and was knotted at 1cm to create a loop, then pulled through the tendon for 10mm. Uniaxial tensile loading using a Mach 1 micromechanical machine generated load deformation curves, and specimens were examined under paraffin and polarised light microscopy.

Results: The initial cheese-wire force of a suture through sheep tendons was similar to human tendons, and more force was needed to pull the suture loop through pig flexor tendons. The differences were more pronounced with greater distraction (Figure 1). Birefringent microscopy showed greatest structural waviness and non-linear orientation in the pig.

Discussion: The study shows that, at the point of testing, cheese-wire forces were highest for pig flexor tendons and that sheep tendons were closer to human tendons, suggesting that where human tendons cannot be used for flexor tendon repair tests, sheep are more suitable than pigs.

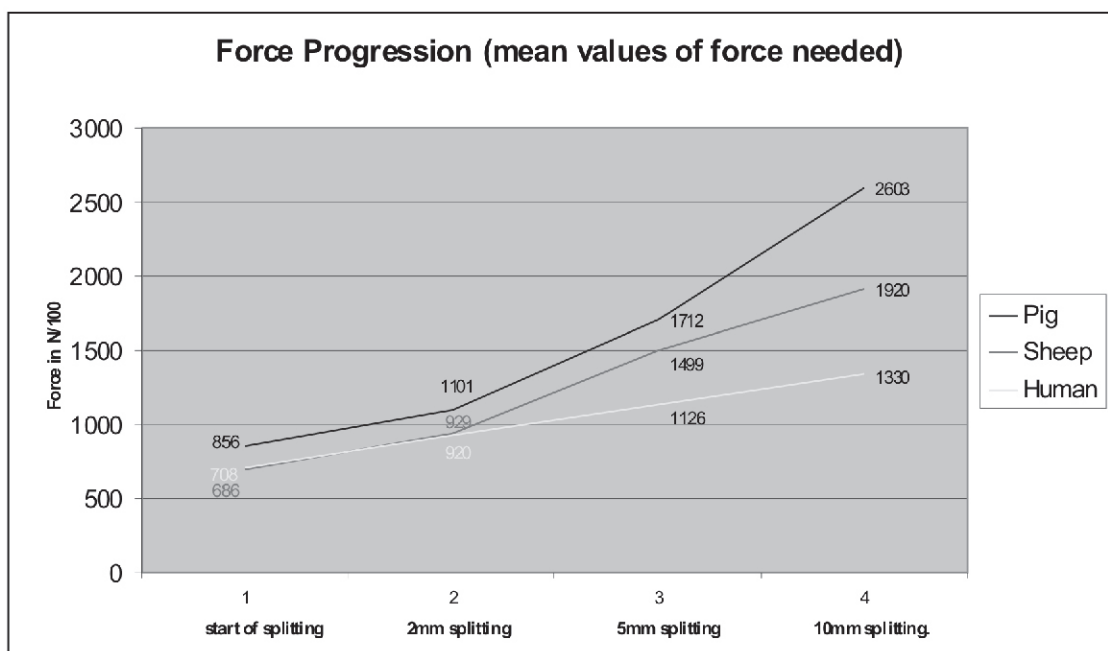


Figure 1

2. **From fins to fists: Evolution of the human hand**

Miss R Zakeri, Mr A Sadr, Mr M Akhavan, Mr R Baker (London)

Introduction and Aims: A complete understanding of hand anatomy, function and pathology requires familiarity not just with embryology but also with evolution. The origins of the human hand can be traced back to the anterior fin of primitive fish, which contains gene patterns identical to those found in limb buds of tetrapod embryos. The aim of this paper is to put hand surgery in an evolutionary context.

Material and Methods: MedLine and Embase were searched for paleontological studies and reviews using terms the “hand”, “evolution”, “human”, “ape”, “hominid”, “anatomy”, “primate”, “forelimb” from 1970 to 2010.

Results and Statistics: There is little discussion in the hand surgery literature about this topic but hand evolution is well described in the anthropological literature. This paper follows the evolution of the hand from the earliest hominids in whom the hand resembled the modern-day orang utan with its long, curved fingers and short, inflexible thumb, through chimpanzee-like ancestors to humans. The human hand is distinguished by its relatively long, strong and opposable thumb and its ability to form both a power grip and precision grip which enabled our ancestors to use tools and develop the skills of clubbing and throwing but also altered the distribution of strain throughout the hand.

Conclusions and Clinical Reference: Evolution has given humanity a uniquely dexterous hand that has been crucial in our origins. The morphological changes in the joints and ligaments help us to understand the pattern of degenerative disease we see in the modern human hand.

3. **Acute paediatric compartment syndrome of the hand caused by hereditary angioedema - A case report**

Mr S S Malik, Mr H Uppal, Mr A Sinha, Mr K Katam, Mr K Srinivasan (Birmingham)

Compartment syndrome of the leg and forearm are well described in the literature and doctors are able to refer such patients to surgeons before it is too late. However, compartment syndrome of the hand is rare and in children it is even rarer. Acute hand compartment syndromes are often associated with multiple closed fractures, snake bites, crush injuries, soft tissue and arterial injuries, and burns. Atraumatic hand compartment syndrome has not to our knowledge been previously reported.

We describe a case of an atraumatic compartment syndrome of hand in a thirteen-year old girl, who presented to the paediatric team with a painful swollen hand. There was no history of trauma, insect/animal bite or compartment syndrome. After an unfortunate two-day delay she was referred to the on-call orthopaedic team with increased swelling and paraesthesia in the median nerve distribution. Clinical examination clearly showed pain on passive extension and she was taken to the emergency theatre for urgent fasciotomy. Intra-operative findings showed a very tight midpalmar space and thenar compartment with a necrotic serosanguinous fluid. This fluid was sterile and subsequent MC&S grew no organisms. She made a good post-operative recovery with no long-term deficits. Further investigations showed her to have a diagnosis of hereditary angioedema.

This case highlights a rare but serious complication of a hereditary disease not commonly seen by the surgical community. Prompt diagnosis and fasciotomy is essential for any compartment syndrome. We hope that this report raises the awareness of this condition and thus reduce delays in reaching a prompt diagnosis.

4. **Histologically confirmed heterotopic ossification of Dupuytren's disease**

Mr H Sadideen, Professor N Athanasou, Mr I McNab (Oxford)

Introduction: Bone and cartilage formation is rare in Dupuytren's disease (DD). We report a case of histologically confirmed heterotopic ossification (HO) in DD and provide an insight into its histology.

Case Report: A patient with DD presented with worsening right small finger contracture and a tight pretendinous cord. During open fasciectomy, dissection of the ulnar neurovascular bundle was hampered by an island of bone-hard tissue within the disease completely enveloping it at P2. Although dissection was slow and difficult, the intact bundle was eventually freed from the disease which was completely excised.

Histological analysis of the surgical specimens revealed foci of proliferative superficial fibromatosis in which there was marked increase in fibroblast cellularity and collagen formation. The nodule was composed of thickened woven and lamellar bone containing fatty marrow. There were focal areas of matrix degeneration and fibrocartilaginous metaplasia around the bone nodule. Immunohistochemistry showed expression of scattered smooth muscle actin (SMA) but not desmin, indicating the presence of myofibroblasts.

Discussion: This HO is distinct from calcification and bony spur development. It was noted in connective tissue containing fibroblasts and (SMA+/desmin-) myofibroblasts. Bone morphogenetic proteins are expressed by Dupuytren's cord fibroblasts and myofibroblasts, and could play a role in inducing metaplastic cartilage and bone formation in DD. The presence of such tissue may be a severe impediment to safe dissection of the neurovascular bundles. It should be treated carefully if encountered and accurately documented in order to guide any further surgery for recurrent disease.

5. Infected palmer and plantar pits: A rare presentation of Gorlin's syndrome

Mr T Weerasuriya, Mr R Swaminathan (Ashton-under-Lyne)

Introduction: Gorlin syndrome is a rare, autosomal dominant cancer syndrome. We wish to present an unusual presentation of Gorlin's syndrome where the presentation involved plantar and palmer pit abscesses.

Case Report: A fifty year old lady presented with palmer and planter abscesses. The patient walked in with an article giving details of Gorlin's syndrome. She had an incision and drainage of a palmer pit abscess on her left non-dominant hand as well as of a planter pit abscess on the ipsilateral foot. Histology was compatible with Gorlin's syndrome. The patient had basal cell lesions, multiple jaw cysts, early onset osteoarthritis, bifid ribs, conjunctivitis and sensitivity to radiation.

Discussion: The genetic locus for Gorlin syndrome is 9q22.3-q31, 3, 4. These patients can develop multiple neoplasms, including basal cell carcinomas and medulloblastomata and from an orthopaedic point of view they present with palmer and planter pit abscesses and early onset osteoarthritis. Regular follow-up of the patient, genetic counselling and follow-up of children with imaging for the development of medulloblastoma is important.

6. Simultaneous traumatic dorsal dislocation of carpometacarpal joints of all four fingers

Mr M S Arshad, Dr L Wilkinson, Mr R Swaminathan (Manchester)

Carpometacarpal dislocations are commonly seen in the emergency setting albeit the involvement of more than one finger is not so common. Frequently, such injuries are a result of high energy trauma sustained within a road traffic accident context.

Over the years there have been reports of carpometacarpal dislocations involving more than one joint. We aim to highlight some of the common reports within the literature to date on such injuries and their modes of management and also present a case of our own.

7. Palm swelling due to anomalous flexor digitorum superficialis of the brevis type - A review of the phylogeny of this muscle

Mr W Bhat, Mr A Akali, Professor S P J Kay (Leeds)

Symptomatic palm swelling is an interesting entity requiring careful evaluation and diagnostic imaging for management. Surgical excision is indicated for histological confirmation and symptomatic relief. Anomalous flexor digitorum superficialis though rare, presents as a diagnostic dilemma. We present the case of a thirty year old woman who was referred with a painful progressive left palm swelling. Following surgical exploration, an anomalous flexor digitorum superficialis brevis to the index finger was found and excised. This is only the third clinical report in literature of this particular type of anomaly. A review of the phylogeny and classification of these anomalies is presented.

Conclusion: There has been no previous report of triggering as a presenting symptom that is possibly explained by the large hypertrophic brevis muscle impinging on the A1 pulley of the flexor sheath. We hope this clinical and phylogenetic review with the revised classification will improve the awareness and understanding of the developmental basis of flexor digitorum superficialis hand anomalies.

8. Abnormal first web space anatomy in fresh cadaveric specimens

Ms R Chawla, Professor P McArthur (Birmingham)

Introduction: Awareness of the existence of anatomical variations is clinically useful in the planning of tendon repairs/transfers. Furthermore there have been reports of clinical variations of supernumerary extensor tendons which can result in clinical signs and symptoms which hand surgeons must be aware of. We present two cases of abnormal first web anatomy, discovered during routine dissection sessions. It may be that these abnormalities are more common than previously thought.

Method: During routine dissection of thirty fresh frozen cadaveric upper limbs, aberrant extensor tendons to the thumb were discovered in two separate cases. The variations lay in the plane between extensor indicis proprius and extensor pollicis longus tendons, inserting into the dorsal surface of the base of the proximal phalanx of the thumb. Associated with this abnormality was the further variation of an accessory tendon to extensor indicis, creating a 'Y' shape anomaly.

Result: Two of thirty (6.7%) dissected upper limbs were found to have this anomaly. The occurrence of an accessory extensor muscle, providing its own attachment to the thumb has been reported as being extremely rare. No additional communication to extensor indicis has been reported prior to this and we present the first series of this anomaly.

Conclusions: It is important to report this new anomaly and use this report to revisit variations, as these variations can cause physical symptoms and knowledge of anatomical variations is important when planning surgical procedures in this region.

9. **Rare case of melorheostosis affecting the thumb**

Dr A Memarzadeh, Mr R Swaminathan (Ashton-under-Lyne)

Introduction: Melorheostosis is a rare benign bone dysplasia. It presents as multi-focal lesions in the long bones of lower and upper limb with a rare predilection to bones of the hand and foot. We describe a case affecting the thumb in isolation. This is the second report of melorheostosis of the thumb in the English literature.

Case: This forty-seven year-old man presented with recent exacerbation of pain and stiffness in his right thumb, which had been present for 20 years. Examination showed a pea sized bony swelling over the radial aspect of the proximal phalanx of the thumb. Inter-phalangeal joint movement was reduced to 0-30 degrees with no abnormal neurology. X-ray showed a dense sclerotic bony lesion within the radial condyle of the proximal phalanx with narrow zone of transition. The lesion resembled dripping candle wax. Bone scan showed a well localised unifocal hot spot in the area where the lesion was found in the X-ray. MRI scan showed expansion of the lesion into the cortices and excision biopsy confirmed the diagnosis of melorheostosis.

Discussion: Melorheostosis is a non-familial condition, but recent research suggests a genetic aetiology. Mutations in the LEMD3 gene have been identified in some affected cases. There are about three hundred reports of melorheostosis, mostly affecting the long bones of the limbs. This rare case highlights that the smaller bones can also be affected by the condition. Furthermore, melorheostosis should be considered as a differential diagnosis to malignancy when investigating sclerotic bone lesions.

10. **Isolated capitate non-union - delayed treatment with Acutrak screws and iliac crest bone graft**

Mr I Roushdi, Dr T Jeswani, Mr D Clark (Worthing)

Introduction: Isolated capitates injury is a rare but frequently missed injury, which can be a source of considerable morbidity as it seems to occur in the young, active population.

Case Presentation: A twenty-four year old left handed roofer sustained a fall from a ladder injuring his right wrist. He was initially treated for an undisplaced distal radial fracture and discharged. He re-presented a year later with pain and clicking in the wrist and an old capitates fracture was identified on plain X-ray and on CT. Fixation of the fracture was planned but unfortunately he was lost to follow-up for a further year. He again re-presented when his symptoms were interfering with his work. Repeat CT scanning was carried out confirming the fracture had still not united.

Management: Fixation was carried out through a dorsal approach with two Accutrak screws and autologous iliac crest bone grafting. This was carried out thirty-two months from the index injury. He was pain free at rest by twelve weeks and repeat CT scanning was encouraging showing bony bridging of the fracture. He had returned back to full manual work by six months with a near normal range of motion in the wrist. We present a series of pre and post-operative CT images.

Discussion: This case demonstrates that operative fixation of the capitate fracture can provide a satisfactory result even in the presence of an established non-union.

11. Lymphoma presenting as a metastasis to the hand
Mr I Roushdi, Dr T Jeswani, Mr D Clark (Worthing)

Introduction: Soft tissue swellings are frequent presenting complaints in a hand clinic. The vast majority of these can be managed successfully on a purely clinical basis but it is vital to recognise those atypical lumps which require a radiological or tissue diagnosis to guide management.

Case Presentation: A sixty-six year old lady presented with a painful swelling over the dorsum of her left wrist following a fall. This was tender and adherent to the deeper tissues. At the time of presentation she did not complain of any B symptoms (weight loss, night sweats, fatigue). In view of the atypical lump she was referred for further imaging of the mass. MRI revealed a pathological fracture through her hamate with abnormal marrow signal and CT showed a suspicious lytic lesion in the hamate. We present a selection of both MR and CT images. She went on to have an open biopsy of the lump and histology showed the mass to be a B-cell lymphoma.

Management: Following tissue diagnosis the patient was referred on to the haematologists. Staging PET CT showed stage four disease (extensive disease with nodes above and below the diaphragm) and she is currently undergoing potentially curative chemotherapy.

Discussion: Metastatic tumours in the hand represent less than 0.1% of all metastases. While lymphoma does rarely present as a soft tissue mass we could find no other cases in the literature where a soft tissue mass in the hand was the primary presenting complaint which led to a diagnosis of a lymphoma.

12. Mycobacterium marinum dactylitis
Mr I Roushdi, Dr M Chard, Mr D Clark (Worthing)

Introduction: Dactylitis occurs in seronegative arthropathies, sickle cell crises and infectious diseases such as tuberculosis and leprosy and atypical mycobacteria.

Presentation: A sixty-year-old gentleman presented with a six-week history of swelling in his right hand was noted to have a dactylitis of his middle finger with a swollen MCP. His inflammatory markers were unremarkable. A diagnosis of an inflammatory dactylitis was made and he was treated with an injection of steroid to his MCP with good result. The swelling recurred and MRI was undertaken demonstrating tenosynovitis. He was commenced on immune suppression with an improvement in swelling lasting. The swelling recurred accompanied by a serious discharge. Microbiology was negative but an ultrasound of the area showed active synovitis and his immunosuppression was adjusted accordingly. The discharge continued to increase and the patient began to complain of a 'lumpy' feeling in the digit. Repeat MRI was organised revealing multiple rice bodies confirmed at surgery. Microbiological examination of the debrided tissue revealed mycobacterium marinum. We present images from his serial MRI scans.

Management: Two years after his original presentation he was commenced on anti mycobacterial chemotherapy. At clinical review he had regained nearly full range at his MCP and PIPJ however his DIPJ remained very swollen with less than a 10° arc.

Discussion: A retrospective history revealed that he kept tropical fish. This case highlights the need for thorough history taking - particularly where the diagnosis may be in doubt.

13. Apert's Feet: Anatomy, function and gait analysis
Miss R Exton, Ms M Wood, Miss G Smith (London)

Introduction: Apert's syndrome is an autosomal dominant condition, associated with craniosynostosis, mid-face hypoplasia and limb anomalies. Increasing life expectancy has placed greater demands on the feet. We aim to determine the foot anomalies and function impact associated with this condition.

Methods: All patients with Apert's syndrome seen at Great Ormond Street Hospital over a six-month period were identified. Clinical photographs, AP/lateral weight bearing radiographs obtained. Gaitrite analysis performed and Oxford Ankle Foot Questionnaire (ISIS innovation) completed.

Results: Of the twenty-six patients 54% had type 3 feet. Radiographs (31 patients) highlighted new findings of talonavicular joint fusion (13%), mid-metatarsal fusion with rotation of 1st metatarsal over 2nd (20%). Gait analysis revealed reduced velocity, shorter step length with wider support base. Questionnaires completed by fifteen children and 24 parents, with 76% children reporting functional problems, 50% footwear problems and 30% appearance concerns.

Discussion: Foot anomalies in Apert's syndrome are not well studied, with management remaining controversial. Talonavicular fusion is previously unreported. Gait analysis revealed reduced velocity, step length and increased base of support. The questionnaire reveals a high incidence of functional problems for this group. This study highlights the anatomical and functional anomalies affecting the feet, providing a baseline to commence analysis of interventions.

14. **Familial cleft hand anomalies**

Mr N T J Hamnett, Mr A Mishra, Professor P McArthur (Liverpool)

Aim: To demonstrate the presence of worsening phenotypical expression of typical cleft hand anomalies in three subsequent generations.

Methods: We discuss the case of monozygotic male twins that presented to the congenital hand and upper limb service. Abnormal antenatal scans reported the possibility of abnormal limbs. Both twins were born with bilateral cleft hand deficiencies. Twin one has an absent thumb post on the left. There are two digits on the right hand, one of which is a thumb. Twin two is more severely affected with the total absence of any thumbs with only a single digit in both hands. Interestingly, both the twins' father and paternal grandfather share the same anomaly. The severity of which has increased with subsequent generations. The father and grandfather have sufficient functionality of their hands to enable them to work, in the transport industry and manual labour, neither requiring operative intervention. Both twins will require varying degrees of surgical intervention if they are to realise their potential, with regard to their overall hand function.

Conclusion: Transmission of this debilitating autosomal dominant condition has previously been described as having strong autosomal inheritance with variable penetrance. We have presented a case of worsening familial cleft hand and feet in three subsequent generations. This case highlights the importance of genetic testing and therefore the role of the geneticist in the multidisciplinary congenital hand clinic so the genetic counselling can be offered to the parents regarding the mutational analysis of this and possible future pregnancies.

15. **A severe, untreated form of Apert's of the limbs : A case report and review of the literature**

Ms K Nelson, Mr N Hamnett, Mr A Mishra, Mr M Nixon, Professor P McArthur (Liverpool)

Introduction: Syndactyly, symbrachydactyly and elbow dysfunction are limb abnormalities associated with Apert's syndrome. Correction at an early age improves development of fine and gross motor skills and can ultimately offer patients a more independent life. We present the case of a twelve-year-old refugee with severe untreated Apert's syndrome approaching skeletal maturity, and the interesting clinical and social challenges that ensued.

Case Report: Upper and lower limbs were severely affected. Elbows were fused in thirty degrees of flexion. Complex complete syndactyly affected all digits. Radiographs revealed fusion between the humerus and shortened radius with an abnormal proximal ulnar and humeroulnar joint bilaterally. Carpal bones were fused. Metacarpal bones were present with distal fusion of the digits. Functionally no fine motor skills had developed but she could lift using her forearms. Wrists were mobile but she was unable to reach her mouth due to the bilateral elbow synostosis meaning she was completely dependant. Gross lower limb motor skills were delayed - standing unaided at three years and walking at four years.

Management: Four months following presentation the right first web was corrected with a dorsal transposition flap and FTSG. At one year she is able to use a spoon and a fork and can write her name and attend school.

Conclusion: This is an opportunity to review the clinical, radiological and developmental features of a previously untreated severe form of Apert's syndrome. It is also a chance to report how previously drastically impaired social and psychological development can be improved.

16. Surgical outcomes for Dupuytren's disease: Fasciectomy v dermofasciectomy - Which surgical technique and when?

Mr S Hindocha, Mr A Hweidi, Mr A Mishra, Miss L Feldberg, Mr A Iqbal (Liverpool)

Introduction: Dupuytren's disease (DD) is recurrent following surgery. Recurrence can be as high as 75%. Dermofasciectomy has led to recurrence rates falling to below 12%. Despite this a dermofasciectomy has a higher complication risk. However, a fasciectomy done at the correct time can result in similar recurrence rates to the dermofasciectomy. This study aims to evaluate the outcomes following each surgical technique between two hand surgeons.

Methods: DD cases performed between two hand surgeons were recorded over the last five years. Operative technique, complications and patients demographic data were tabulated. Surgical outcome over a five-year period was recorded. Operative notes on check rein release was searched.

Results: Three hundred and fifty-eight DD cases over five years were evaluated. Recurrence rates were 75% for those undergoing a fasciectomy and 50% in those having a dermofasciectomy. However, diathesis for each patient in each consultant and operative group varied. Severity score in each patient group varied. Documentation of the check rein release was not mentioned.

Conclusions: Despite widespread research on operative technique for DD guidelines are not based on severity scoring or DD diathesis. In addition the release of the check rein has been shown to reduce PIPJ contracture rates, yet this has not been statistically evaluated in DD. We propose a novel set of guidelines for the clinical management of DD.

17. Fractures of the middle and proximal phalanges in children

Mr A Samuel, Mr P Jesudason, Mrs F Peck, Professor D A McGrouther (Manchester)

Introduction: The phalanges are the most common site of bony injury in children. Most children's hand fractures can be treated without surgery as they have a remarkable ability to remodel moderate fracture malalignment, especially in the sagittal plane. In contrast, children cannot remodel mal-rotation, which requires reduction and stabilisation to prevent digital scissoring.

Aims and Methods: Our aim was simply to assess the range of injuries seen within our unit and to assess clinical outcome. We present a consecutive series of forty-five children presenting to the hand therapy-led trauma clinic between January 2009 and 2010, with suspected fractures of the proximal or middle phalanx. We excluded all distal phalangeal and nail bed injuries. These patients were identified from the hand therapy trauma register and the fractures were classified broadly into intra-articular and extra-articular fractures; and further subdivided into physeal, shaft and phalangeal neck fractures.

Results: Of the forty-five patients reviewed in the hand therapy trauma clinic, 8 patients were reported not to have a fracture, 15 had physeal injuries, 2 had shaft fractures, 29 were proximal phalangeals, 2 were intra-articular fractures and 3 were phalangeal neck fractures. Of these, only one child with a spiral shaft fracture was treated with internal fixation.

Discussion: Our data confirm that the majority of phalangeal fractures in children can be effectively managed conservatively. Injuries that do not remodel or highly unstable fractures should be surgically stabilised.

18. A plastic surgical prosthetics department's five-year experience with the use of finger prostheses

Mr K Anderson, Mr D Dewing, Ms G Woolley, Ms J McPhail (Liverpool)

Introduction: The aim of our review was to analyse the case mix and outcomes with the use of prosthetic fingers in our department with a view to improve the service we offer.

Method: We carried out a retrospective case note review of all patients referred to our prosthetics unit over the last five years who had received prosthetic fingers.

Results: There were forty-eight patients with 67 fingers involved. The gender mix was even with twenty-five female and 23 male patients. The age range was from thirteen to 76. Referral profiles were predominantly secondary to crushing (15, 31%) or cutting trauma (14, 29%) resulting in terminalisation of part or all of a digit. Ten patients had multiple digits involved. Complications encountered included neuroma in nine (19%), nail spikes in 3, infection in 2 and phantom pain in two cases. We found these patients demonstrated that their traumatic injuries had consequences resulting in psychological morbidity. Prior to injury six patients had previous history of psychological morbidity and post-injury 22 (46%) had such problems. Of these, nine (19%) required specific treatment. Twelve out of the 22 had improvement in their mental health after fitting of a prosthesis. 65% expressed satisfaction with their prosthesis and 11 (23%) showed functional improvement with a prosthesis.

Conclusions: Our prosthetic fingers have been shown to provide satisfactory cosmesis. Where psychological morbidity is an issue, a prosthesis may help. Some patients also have functional benefit from a prosthesis. We recommend these patients be offered consultation with a prosthetist.

19. The epidemiology of hand fractures

Mr E Laugharne, Mr D Bhavsar, Mr V Rajaratham

Introduction and Aims: At our regional hand centre we are exposed to a variety of hand injuries, both simple and complex, that either present directly or are referred from other hospitals. We wanted to establish the demographics of our patients, the distribution of fractures and how they were managed.

Methods: We searched our emergency department records for the last one thousand hand fractures (i.e. distal to the carpus). So far we have information on three hundred and twenty-five patients (the full 1000 patients' data will be presented at the meeting).

Results: Three hundred and twenty-five patients (345 fractures): 248 males (72%), 77 females, mean age 31 years (mean age of males 28yrs, females 42yrs). The right hand was involved in two hundred and nineteen cases, the left in 109. The most common mechanism of injury was punching, followed by falls and crushing. Sixteen patients sustained more than one fracture to the same hand. The small finger ray was the most frequently fractured (183 fractures), then ring (63), middle (37), thumb (35) and index finger (27). The small metacarpal was the most commonly fractured bone (133 fractures), with the distal third/neck accounting for 63% (24% of all fractures). The majority of patients (85%) were managed conservatively. Surgical treatment was more common in multiple fractures.

Conclusions: The majority of our patients were young males sustaining punching injuries. The most common fracture was the neck of the small metacarpal, the bulk of which were managed conservatively.

20. The importance of fracture reduction in the aetiology of flexor pollicis longus ruptures after volar plating of distal radial fractures

Miss C Simpson, Miss P Thorpe, Mr D Brown (Liverpool)

Introduction: Flexor pollicis longus (FPL) are widely reported following volar plating of distal radius fractures. The role of plate position in the aetiology of these ruptures has previously been presented to the Society. In this study the role of fracture reduction is investigated.

Method: Using twenty identical 'anatomic' distal radial saw bones an 'anatomic' (Acu-loc) plate was positioned in an anatomic position and this position marked. Wedge osteotomies were then created using purpose made cutting guides to simulate mal-reductions of 5, 10, 15 and 20 degrees. The increase in resulting plate prominence was measured as was the enforced proximal migration of the plate, required to prevent articular penetration of the distal screws.

Results: The results are shown in the following table where P1 is significance in the change from anatomic and P2 is the change from the previous reading.

Discussion: Even 5° of mal-union causes a very significant increase in plate prominence which is also clinically significant (over 4 times as prominent as when in anatomic position). This is compounded by the fact that 5° of mal-union also enforces a significant amount of proximal migration of the plate (which has previously been shown to also increase plate prominence)

Conclusion: Accurate fracture reduction is essential to ensure anatomic fit of volar plates. Failure to achieve this increases plate prominence and pre-disposes to flexor tendon irritation and rupture.

21. Paediatric hand fractures in a tertiary referral centre

Miss K Young, Dr A Greenwood, Mr A McQuillan, Mr S Lee, Mr S Wilson (Bristol)

Introduction: Hand fractures account for up to one fifth of all fractures, with incidence peaking in the teenage years.

Aims: To review the incidence, demographics, morphology and management of paediatric hand fractures.

Methods: Retrospective review of the notes of children attending a tertiary referral centre in the South West of England with hand injuries over a year. Non-boney injuries were excluded. A total of three hundred and three fractures in 283 patients were reviewed.

Results: The annual hand fracture incidence was twenty-two per 10,000. Incidence rose sharply after the age of seven and peaked at fourteen years of age. The mean age was 12.1 years. Of the three hundred and three fractures, 231 (76%) were in males and 72 (24%) females. Sporting injuries were responsible for one hundred and forty-three (47%) of all fractures. The dominant hand was not fractured significantly more than the non-dominant. The proximal phalanx of the little finger was the most commonly fractured bone. Physeal fractures accounted for one hundred and eighteen (39%). Open fractures were rare, and were associated with nail bed injuries in all but four cases.

Management was primarily conservative. 85% of all fractures were splinted, and in 66% splint was the only treatment. Fifteen fractures (5%) required fixation. Just under half of all fractures were referred for hand physiotherapy. Long-term sequelae were rare.

Conclusion: Hand fracture incidence is known to peak in the late teenage years. This study enables the review of paediatric hand fracture aetiology, morphology and management, and the comparison to that of hand fractures presenting in adults.

22. What determines the middle phalangeal length: A review of one hundred consecutive plain radiographs

Mr N T J Hamnett, Mr A Mishra, Mr S Hindocha, Professor P McArthur (Liverpool)

Aim: To determine why the middle phalanx is, in most cases, the longest of phalanges.

Patients and Methods: One hundred consecutive plain radiographs of the hand were reviewed. Measurements were taken digitally to two decimal places on life size radiographs. Index and middle metacarpal lengths were measured from the base of metacarpal to the head. Phalangeal lengths were measured from the base of the proximal phalanx to tip of the distal phalanx. Index and middle metacarpal and phalangeal lengths were compared.

Results: Paired sample T-tests revealed index metacarpal lengths were significantly longer in all but one case compared to middle metacarpal lengths. Middle phalangeal lengths were significantly longer in all cases.

Conclusion: It is a common misconception that the middle finger is usually the longest digit of the hand because of its superior metacarpal length. This study proves that the length discrepancy is related to the more distally placed middle carpo-metacarpal joint and middle phalangeal length and not a longer middle metacarpal when compared to the index ray.

23. Anatomical zones of the carpal tunnel

Mr M Young, Mr D A Campbell (Leeds)

Carpal tunnel release is commonly performed in hand surgical units around the world. It is often utilised as a training procedure for surgeons because of its high incidence and perceived surgical simplicity. This study describes three distinct anatomical zones through which the median nerve passes as it traverses the carpal tunnel, with practical recommendations to surgeons of all grades as to how to avoid injuring the nerve during surgical release.

Fifty healthy asymptomatic volunteer subjects (100 hands) were examined by non-invasive ultrasound assessment of the depth of the surface of the median nerve from the surface of the overlying skin. Three easily identifiable bony landmarks were identified (radiocarpal joint, capitolunate joint and carpometacarpal joint) and depth measurements taken at each of these points. Information was also collected relating to age, gender, hand size and hand dominance. Measurements were recorded with fingers in full extension and in full flexion.

The median nerve passes through three distinct anatomical zones; proximal (median depth = 2.3mm), transitional (median depth = 3.6 mm) and distal (median depth = 6.2 mm) ($p < 0.0001$).

Larger hands (glove size > 7) and male hands were found to have deeper nerves throughout their course.

This study accurately describes new zonal anatomy of the depth of the median nerve as it traverses the carpal tunnel. This is relevant in clinical practice, especially as many of these procedures are performed by trainee surgeons who may be unaware of the depth of the nerve as they incise the skin.

24. **Contralateral innervation of fingertips: A clinical review**

Miss M Mughal, Dr R Ching, Mr R Pinder, Mr W De Jager (Bradford)

Introduction: The loss of digital sensation from nerve injury can be very disabling. Several methods of nerve injury repair have been described which report varying degrees of sensory return. The presence or absence of crossover sensorineural supply of each digital nerve is not documented in the literature, and the degree to which any crossover exists will effect reported results of nerve repairs. We aimed to assess contra lateral nerve supply in fingertips.

Methods: Patients who had traumatic division of an unilateral digital nerve repair were followed up at three weeks post-operatively. Two point discrimination and Semmes-Weinstein monofilaments were used as diagnostic tools to assess sensation at the distal end of the finger which was divided into four quadrants, one side being the uninjured nerve whilst the other denoting the repaired side.

Results: A total of seven patients were followed up. Six patients had direct nerve repair whilst one patient with multiple hand traumas did not. The static two-point discrimination among all patients was within the range 8-20mm. Six patients scored S3 (MRC grading system) on the injured side. On follow-up one patient complained of reduced sensation on the uninjured side but scored S4 on the repaired side.

Conclusion: It appears from this small study that there is some contribution to sensory supply of the fingertip from the contra lateral digital nerve. Although we have no doubt that further advances in nerve repair are much needed, we advise caution in the interpretation of results of studies advocating new techniques.

25. **Dexterity and functional recovery**

Miss N Darhouse, Miss A Alexander (Oxford)

Introduction: Surgical or traumatic wounds of the hand and wrist cause restriction of hand function and discomfort during the healing process and can have long-term cicatricial complications. Prolonged discomfort during the healing process can lead to CRPS and long-term functional deficit. Hand and scar therapy is critical in prediction and prevention of these complications. Carpal tunnel decompression is a frequently performed standardised procedure resulting in comparable scars over the palm and distal wrist.

Aim: To assess whether a scar on the dominant hand causes more discomfort and limitation of function.

Method: A retrospective review of carpal tunnel decompression procedures performed in our Trust during twelve months. Cases which underwent bilateral procedures by surgeons of the same level of competence (training level) in the day surgery unit and offered the same follow-up programme were selected. Patients with confounding comorbidities or a history of hand trauma and those who developed early wound complications were excluded. A modified Disabilities of the Arm, Shoulder, and Hand (DASH) Questionnaire was completed for the dominant and non dominant hand. Any case which scored worse for the dominant hand on the DASH score was considered a positive finding.

Results: Fifty-six cases were eligible for the study. Patients were grouped depending on employment status and type of work into four groups as follows: A – Retired; B - Non-manual work; C - Manual work (ambidextrous); D - Manual work (dexterity dependant).

Group	n	Dominant hand resulted in a poor recovery	r	p
A	11	1	0.09	0.7
B	17	0	0	1
C	12	1	0.08	0.75
D	16	13	0.8	0.0001

Conclusion: Scars on the dominant hand or wrist in dexterity dependant manual workers result in less favourable recovery and slower resumption of normal activity and work.

Discussion: A thorough history and proper consideration of the patients work, hobbies and normal daily activities is essential and would help predict outcome. Practices should consider increasing hand and scar therapy sessions for patients with healing wounds on their dominant hand if they are manual workers dependant on the dominant hand. Patients should be informed of the possible effect it would have on their functional recovery and consider offering endoscopic or less invasive options for this group.

26. **Two for the price of one - The impact and cost of multiple pathologies in elective hand patients**

Miss A Murray, Miss P Tay, Mr S Southern (Leeds)

Introduction: A significant number of patients referred to elective hand clinic were noted to have more than one hand pathology. Such additional pathologies often require separate investigations or interventions. The aim of this audit was to determine the actual additional cost and workload associated with this group of patients.

Method: All new and follow-up patients seen in Pinderfields elective hand clinic were assessed for a two-month period and entered into the audit as appropriate. Any patient who gave symptoms of an additional hand problem, other than the one for which they had been referred, was included in the audit. A proforma was used to document key points, including whether any intervention was required for the additional problem.

Results: Out of sixty-four new patients and 141 follow up patients seen:

- 31.3% of all new patients had an additional upper limb problem
- 28.1% of all new patients had an additional upper limb problem requiring intervention
- 3.5% of all follow-up patients had an additional upper limb problem requiring intervention
- Each of these patients costs the trust an average of £251.05 extra (i.e. in addition to the fee requested from the PCT) per clinic visit
- Over a one-year period, this equated to a total loss of income of £68,093.80.

Conclusions: It has been shown that a significant number of elective hand patients present with multiple pathologies, although are only referred with one. The provider needs to be aware of the potential shortfall in funding when negotiating with purchasers.

27. **A simple dorsal web space block for hand surgery procedures**

Mr S Rimouche, Professor D A McGrouther (Manchester)

Many options are available for anaesthesia of hand surgery. Regional blocks, when used in proper settings and patient population, have a unique application for procedures of the hand. We describe dorsal web space regional block which we use routinely for both traumatic and elective hand surgery procedures. Just proximal to the metacarpal head, over the dorsal web space local anaesthetic is infiltrated using a fine needle at ninety degrees to the skin aiming at the volar aspects of the hand. Simultaneously gentle pressure is applied at the same volar area. The needle is advanced slowly and with care in order to obtain a good field block targeting the common digital nerve. Different anaesthetic agents and concentrations could be used upon surgeon preference. Agents containing non-adrenaline could also be used to provide longer duration

of action, lower risk of adverse systemic effects and reduce bleeding at the surgical site. Patient distraction techniques are employed to reduce anxiety. We found dorsal web space blocks to be simple, safe, reliable and effective. They provide adequate surgical field which include two half digits and the distal part of the corresponding palmar area. This field could be extended by the use of multiple blocks. Dorsal web space blocks have significant advantage in eliminating the risks associated with general anaesthetic and also regional plexus blocks with providing adequate surgical field. It does not require the presence of an anaesthetist. They also enable less extensive patient pre-operative investigations, starvation and its associated health and socio-economic benefits.

28. Injection of Botulinum toxin in the upper limb: Accuracy of placement using manual palpation and surface markings

Mr K Anderson, Mr A Elgawad, Ms J McPhail, Professor P McArthur (Liverpool)

Introduction: Botulinum toxins are used to treat focal spasticity of muscles in cases of cerebral palsy and brain injury. An important factor of successful treatment is accurate delivery of toxin. The aim of this study was to record the accuracy of injection into the upper limb muscles frequently treated by botulinum toxin, using the method of palpation and surface markings alone.

Material and Methods: Neurological and neurorehabilitation clinicians, experienced in the use of toxin therapy attend an upper limb anatomy instructional course. Cadaveric specimens are injected. Surface markings and palpation is the localisation technique used and accuracy of injection of target muscles was assessed. All clinicians agreed to take part in the anonymised study.

Results: In total thirty-six clinicians carried out 324 injections into 9 upper limb muscles. The overall positive target hit rate was 58.3%. Flexor pollicis longus had the lowest hit rate with only seventeen positive hits from the 36 injectors (47.2%). The most successfully targeted muscle was flexor digitorum profundus (66.7%). There were two incidents of injection directly into a major nerve and one intra-arterial injection.

Conclusion: Anatomical landmark and palpation alone has a low success rate of hitting the targeted muscle. We would recommend that injections be carried out with additional localisation techniques such as USS, when delivery of toxin can be visualised or EMG.

29. Cavi-care dressings following syndactyly correction

Mr N T J Hamnett, Mr A Mishra, Professor P McArthur (Liverpool)

Purpose: To present a novel and pain free method of dressings for syndactyly correction.

Methods: Traditional dressings following release may become saturated and require frequent painful dressing removal as they dry out making them difficult to remove. Cavi-care dressing is a sponge dressing traditionally used for pressure sores and hypospadias. Cavi-care is now our dressing of choice for all syndactyly release and paediatric elective hand surgery patients. Cavi-care dressing liquid is mixed, the fingers are held separated and the Cavi-care liquid is poured within a plastic cone template applied around the hand to the wrist. Polyfax ointment is applied to the wound. This liquid sets in three minutes into a sponge, keeping the fingers splinted and separated. Crepe bandage is applied over this sponge dressing and carried over beyond elbow to avoid slippage in children. It is the practice of the senior author to leave the dressing in situ for two weeks. It has been used in twenty-four patients over eighteen months.

Results: Removal of the dressing, usually by the child is pain free with no adherence to the wound. None of the patients had any maceration or wound breakdown due to the absorbent non-adherent quality of this sponge dressing. Parents of ten children who had staged bilateral procedure and who had initial traditional hand dressing and later Cavi-care dressing found the change of dressing a more comfortable experience.

Conclusion: We would recommend Cavi-care dressings in combination with polyfax ointment for paediatric hand surgery patients and syndactyly repair.

30. Hand trauma and driving - Are the doctors and patients compliant?

Mr S Hindocha, Mrs C Kelsey, Mr D Bell (Liverpool)

Introduction: The regional hand trauma unit will experience a large number of referrals from peripheral primary hospitals. In general, these injuries are not life or limb threatening and the patient in question is asked to attend the tertiary referral centre either on the day of injury or the following day for assessment. It is not entirely clear whether patients are given information regarding their driving activities or whether they are aware the DVLA state they should not drive. We aim to assess how many patients referred to a tertiary referral centre are advised about their driving habits.

Materials and Methods: One hundred patients were prospectively interviewed and asked whether they were assessed and advised with regards to their driving habits.

Results: Less than 25% of patients were advised about their driving habits from the primary and tertiary referral centers. Neither A&E nor hand surgery departments appeared to verbally advise or document whether a patient was driving with a hand injury or post-operatively. There were many a time where patients with hand injuries and post-operatively were driving.

Conclusion: Driving with a hand injury or following hand surgery will invalidate insurance and has legal consequences. It is vital that all health professionals are educated regarding hand trauma and driving regulations and that these are recorded in the patient case notes for medico-legal purposes. Specialist hand surgery units should also educate peripheral referring centers of this guideline.

31. Growth trends analysis in hand transplantation: Divergence between clinical volume and scientific output

Miss T S Win, Mr J Henderson (Chelmsford)

Introduction: Since 1998, when the first successful hand transplant was performed, it is established that hand transplantation is both technically and immunologically feasible. Despite initial enthusiasm, hand transplantation, a decade later, remains experimental. This study looks at the growth trends in the field.

Methods: The international registry on hand and composite tissue transplantation (www.handregistry.com) was used and the number of hand transplants performed annually according to the geographic distribution was analysed. A Pubmed search using the term 'composite tissue transplantation' was performed, and articles (all languages, published between January 1998 - December 2009) relevant to hand transplantation were selected to analyse the publications in the field. The selected articles were further divided as reviews or original research articles (including case reports).

Results: The number of centers performing hand transplants: Europe 8, Asia 5 and North America 2. A total of fifty-two hands/digits has been transplanted in 38 recipients (1998-2009). The annual volume of clinical hand transplants has remained low (average number of hand transplants per year = 3). However, there has been a steady increase in the scientific literature during this period.

Conclusions: After more than a decade since the first successful hand transplant, the clinical volume remains low. This is likely due to the need for long-term systemic immunosuppressants. This has resulted in the intense search for mechanisms to induce immune tolerance, reflected by an increase in the number of publications over the recent years.

32. Managing volar plate injuries in children: A case series

Mr D Nikkhah, Mr J Rodrigues, Mr W De Jager (Bradford)

Introduction: We present a review of the evidence describing volar plate injury treatment in children, and a case series of the management of such injuries of the thumb MCPJ in children treated at a single UK hand unit.

Methods: OvidMEDLINE was searched for the term "volar plate". The management of three cases of closed isolated volar plate injuries presenting to a single centre was retrospectively reviewed.

Results: Two hundred and sixty-nine articles were identified. Of these, only one was relevant, and described the non-operative management of stable volar plate injuries in children. Three girls aged 2, 11 and 12 years presented with painful swan neck deformities of the thumb. MCPJ hyperextensions of 45, 23 and 60 degrees respectively were present. Two were traumatic and one was spontaneous. All three patients were initially treated non-operatively with thumb spica splinting for a minimum of four weeks. After this, all three thumb MCPJs collapsed back into symptomatic hyperextension. For the older two, thumb MCP joint volar plate plasties were performed, and EPB's insertion was also transferred to the metacarpal base. Given the young age of the third patient, repair was considered unsuitable due to the immature nature of the metacarpal bone.

Discussion: There is a marked paucity of published literature guiding the management of these injuries in children. Our series suggests that unstable painful thumb MCPJ volar plate injuries in children might require surgical intervention if non-operative treatment fails. However, further evidence is needed to optimise the treatment of volar plate injuries, especially in young children.

33. **A modified way to provide scapholunate stability using a slip of flexor carpi radialis tendon: A report of three cases**

Mr R Chopra, Professor R Murali (Wigan)

Scapholunate ligament reconstruction using a slip of flexor carpi radialis tendon has been described in the past. We present a modified way of using flexor carpi radialis tendon slip to reconstruct the scapholunate ligament in the wrist and early outcome of three cases.

Surgical Technique: Through a small volar curved incision the flexor carpi radialis (FCR) tendon is harvested. A dorsal incision is then made to expose the wrist between the third and fourth extensor compartments. The extensor retinaculum is split and the wrist joint is exposed at the level of the scapholunate joint. A tendon passer is inserted from the dorsal side of the distal aspect of the scaphoid and passed anteriorly just lateral to the distal pole of scaphoid. The harvested slip of FCR tendon is passed around the distal pole of scaphoid and delivered out dorsally. The FCR slip is anchored around the posterolateral aspect of the scaphoid as it enters into the dorsum of the wrist joint with non-absorbable suture. The FCR slip is attached to the lunate with the help of an absorbable anchor. The capsule on the dorsal side of wrist is then approximated incorporating the slip of FCR tendon.

Conclusion: By modifying this already modified technique we present an easier and safer way to stabilise the scapholunate joint. The FCR tendon slip across the distal pole of scaphoid acts as a hammock and stabilises the scaphoid bone in its place providing carpal stability.

34. **Sesamoid arthrodesis of the thumb interphalangeal joint**

Mr A Nicholls, Mr T Crook, Mr D Hargreaves (Southampton)

Introduction: Symptomatic thumb interphalangeal (IP) joint hyperextension is uncommon but may be functionally disabling. However, there is little evidence of surgical treatment options. In the presence of an intact volar plate and an interphalangeal sesamoid bone, sesamoid arthrodesis allows for effective joint stabilisation, maintaining a functional range of motion. Two young adult male patients presented to the outpatient clinic with symptomatic hyperextension of their dominant thumb IP joint. Conservative treatment with extension-blocking splints failed, confirming the indication for surgical correction.

Method: The operative technique used was an adaptation of the sesamoid arthrodesis of the thumb metacarpophalangeal (MP) joint described by Tonkin et al 1995. Through a radial approach to the IP joint capsule the sesamoid bone is fused to the neck of the proximal phalanx using a Mitek mini anchor (DePuyMitek®) thus stabilising the volar aspect of the joint. Post-operative immobilisation in an extension blocking splint for six weeks is followed by active flexion and extension under the supervision of a hand therapist. The presence of a sesamoid bone at the thumb IP joint is a prerequisite for this technique. The reported incidence is variable and has been described between 62% and 100% in some radiological studies.

Results: No post-operative complications were encountered. Both patients were evaluated at a mean follow-up of three years. Hyperextension had been abolished, functional range of motion had been preserved and both resumed their usual level of activity.

Conclusion: Sesamoid arthrodesis is an effective treatment for symptomatic thumb IP joint hyperextension and preserves a functional range of motion.

35. Technical tip: Steroid injection to the basal thumb joint

Mr P Storey, Professor F D Burke (Barnsley)

The arthritic joint is usually tight and fluoroscopy is helpful. If fluoroscopy is not available infiltrate local anaesthetic to bone at base of the first metacarpal and a little more proximally and wait for five minutes. The volume capable of injection into the joint is often low, therefore do not over dilute the depo steroid (perhaps 1ml of steroid to 0.5 ml of local anaesthetic). The plane of the articular surface of the joint is not perpendicular to the long axis of the first metacarpal, therefore tilt the syringe 20° more proximally (fig 1). If fluoroscopy is not available, march the tip of the needle proximally from the base of the metacarpal until the joint is penetrated. When the needle tip has passed through the capsule, inject material under some pressure into the joint. If you now remove your finger from the plunger, steroid and local anaesthetic in the joint under pressure will flow back into the syringe. This 'piston effect' confirms your needle tip is present in the joint (as does a fluoroscan image showing a wider gap between the articular surfaces). Apply pressure to refill the joint and withdraw the needle. If the needle gauge is sufficiently slim (23G or finer) little steroid will leak from the joint with minimal risk of local depigmentation and fat atrophy (although patients should still be advised of this risk).

36. Should fracture fixation using volar locking plates of the distal radius be performed by a hand surgeon? An outcome study

Mr D E Giebaly, Mr J Stevenson, Mr L Murugesan, Mr G Pavlou, Mr I Bhoora (Stafford)

Objective: Determine complication rates following the use of volar locking plates in distal radius fractures, to identify any potential improvements, and to describe functional outcomes following surgery.

Materials and Method: We performed a retrospective data collection on a series of one hundred and seventy-seven patients (178 wrists) admitted for internal fixation of distal radius fractures between January 2007 and December 2009. Twenty-five patients were excluded. One hundred and sixteen female and 38 male with a mean age fifty-four, and a median age of 57 (18-84) were available for follow-up. Case notes were reviewed along with radiographs and functional assessments were recorded using the Disabilities of Arm, Shoulder and Hand (DASH) scoring system and the Patient Rated Wrist Evaluation (PRWE) score.

Results: Total 28% complication rate. Thirteen patients (8.4%) had removal of plate or are listed for removal. One patient had a fasciotomy following compartment syndrome, one patient had revision surgery, one deep wound infection requiring removal, two superficial wound infections and one patient with post-op DVT. Seven (4.5%) had inadequate reduction following surgery, and 11 (7.14%) were complicated by further collapse following reduction. Mean DASH scores were 10.3 and did not correlate with X-ray appearances post-reduction or with fracture classification.

Conclusion: In our case series, complications following surgery remain high. Fixation with volar locking plate seems to be suitable for AO B type fractures of the distal radius. Careful consideration of the risks of surgery, with operating preferably under the supervision of upper limb consultants for the other AO fracture configurations and dorsally displaced fractures.

37. The Kirk Watson test predicts increasing instability at the scapholunate joint when compared with an arthroscopic classification

Mr C Peach, Mr R Wain, Mr M Woodruff (Manchester)

Aim: To evaluate the correlation between the clinical Kirk Watson test and arthroscopic Geissler classification in scapholunate instability.

Methods: Kirk Watson tests and Geissler grades of all wrist arthroscopies between April 2006 and April 2010 were evaluated. Geissler grades 1 and 2 and grades 3 and 4 were grouped for further analysis into low and high grade instability groups respectively.

Results: Seventy-six patients were included. Sixty-two had scapholunate pathology and 14 had normal arthroscopic findings. A positive test was found in 30% (3) of patients with grade 1 instability, 29% (4) with grade 2, 60% (12) with grade 3 and 78% (14) with grade 4 instability. The test was positive more commonly in those with grade 4 instability compared with others (78% vs. 43%; $p=0.015$). There was a higher number with a negative test in the low grade instability group (71% vs. 32%; $p=0.01$) and a higher number with a positive test in the high grade instability group (68% vs. 29%; $p=0.006$).

Conclusions: The Kirk Watson test is a sensitive and specific test for diagnosis of higher grade instability of the scapholunate joint. We found a positive correlation between increasing scapholunate instability when assessed using the Geissler classification and positivity of the test. This confirms that the Kirk Watson test can be a useful test in the assessment of those with symptomatic instability of the joint and may reflect damage not only to the scapholunate interosseous ligament but to the secondary stabilisers of the joint as well.

38. What is the plane of the dart-thrower's motion of the human wrist?

Mr G Brigstocke, Mr A Hearnden, Dr G Whatling, Dr C Holt (Guildford)

Introduction: The dart-thrower's motion (DTM) is an oblique plane of global wrist movement from a position of radial extension to ulnar flexion. Static computed tomography based cadaveric studies have defined a plane of the DTM at 45° to the sagittal plane of the forearm that correlates with minimal proximal carpal row motion. The aim of this study was to define in-vivo how obliquely the plane of the DTM inclines to the sagittal plane of the forearm and the variation of this plane between individuals with no wrist pathology.

Methods: Global wrist motion of ten right hand dominant male subjects was recorded using eight Pro-reflex MCU digital cameras (Qualisys, Sweden) at The Cardiff School of Engineering Motion Analysis Laboratory. Retro-reflective marker clusters were positioned on the hand and forearm. Each subject performed six simulated dart-throws. The 6° of freedom between the hand and forearm were calculated and the plane of global wrist motion defined.

Results: The mean plane adopted by the subjects when performing a simulated dart-throw was inclined at 44.7° to the sagittal plane of the forearm from a position of radial extension to ulnar flexion. The standard deviation of this plane was 12° .

Conclusions: This study developed a dynamic in-vivo method of data collection to define the DTM of the human wrist. The DTM defined dynamically concurs with the results of previously reported static CT based cadaveric studies. In-vivo measures of the DTM plane are important for the development of wrist prostheses aiming to preserve this functionally important motion.

MEETING INFORMATION**REGISTRATION FEES**

IMPORTANT NOTICE: Doctors or scientists engaged in research **AND** presenting a paper will not be charged a registration fee for the day they are presenting if they can confirm in writing that they have **no access** to study leave expenses. They must however pay £40.00 per day. This is the day delegate rate charged to the Society by the venue for each individual attending.

Exemption from payment of registration fees is not available to those who have access to study leave. If all study leave for the year has been utilised, full registration fees must be paid.

	Registration Fees
Full / Overseas / Associate Member and Other	£330 Whole meeting £175 One day
Trainees, (UK only) Companion Members	£225 Whole meeting £115 One day
Honorary/Senior Members Speakers who are Research Doctors or Scientists	£40 per day

REGISTRATION AND ENQUIRY DESK

The Registration and Enquiry Desk, (situated in the Quays Bar) will be open at the following times:-

Thursday	08:30 – 17:00
Friday	08:30 – 14:00

The telephone number of the Registration and Enquiry Desk during the Meeting is: 07930 509 646 (BSSH mobile telephone number).

HONORARY AND SENIOR MEMBERS

Honorary and Senior Members will not pay a registration fee. A charge of £40.00 will be made for refreshments and luncheon each day. This is the day delegate rate charged to us by the venue for each delegate.

VENUE OF SCIENTIFIC MEETING

The meeting will be held in the Compass Room.

CONTRIBUTORS' INFORMATION

Projection Facilities

Projection of presentations will be by PowerPoint only. The AV will be provided by the in-house AV Department. Presentations can be checked and loaded in the North Room.

SPEAKERS ARE ASKED TO KEEP STRICTLY TO THE TIME ALLOCATED FOR THEIR PRESENTATION.

POSTER PRESENTATIONS AND POSTER PRIZE

Posters will be displayed in the Quays Bar area. Authors of posters are asked to 'man' their posters during the second half of lunchtime on Thursday and/or Friday in order to provide opportunity for discussion between delegates and authors. The authors of the best poster will receive book vouchers to the value of £250.00.

MEDICAL AND TECHNICAL EXHIBITION

Firms supplying instruments, appliances, materials and books will be exhibiting throughout the two days in the upper & lower Quays Bar areas, where refreshments will be taken. It is hoped that everyone will support this exhibition.

SOCIETY BUFFET SUPPER

The Society Buffet Supper will be held at Imperial War Museum North on Thursday 31st March. The deadline for the purchase of Buffet Supper tickets was 25th March 2011.

LUNCHEON

Luncheon will be served in the Quays Bar.

BUSINESS MEETING

The meeting which is open to members and associates only will be held on Thursday, 31st March at 17:15 in the Compass Room.

CAR PARKING

There is a secure car park at the Lowry Outlet Mall in Salford Quays.

MEETING INFORMATION**HOTELS**

No block bookings have been made, but hotels in walking distance include:

Holiday Inn Media City, Salford M50 2HT

Room rate including breakfast: from £89.00 per room

Website: www.holidayinn.com, Email: reservations@himediacityuk.co.uk,

Telephone: 0161 813 1046, Contact: Madeleine Greenhalgh

Holiday Inn Express Salford Quays, Waterfront Quay, Salford Quays M50 3XW

Room rate including breakfast: from £85.00 per room

Website: www.expressmanchester.co.uk, Email: reservations@expressmanchester.co.uk

Telephone: 0161 868 1000, Contact: Dom Smith

Premier Inn Salford Quays, Salford M50 3SQ

Room rate excluding breakfast: 73.00 per room; breakfast is charged at £7.99

Website: www.premierinn.com, Email: manchestersalford.pi@premierinn.com

Telephone: 0161 872 4026, Contact: Reception Team

Alternative Hotels:

HOTEL	ADDRESS	TELEPHONE	RATE	DISTANCE FROM THE LOWRY
Copthorne Manchester 4*	Clippers Quay Salford Quays M50 3SN	0161 873 7321	From £99 - £145 Room only Subject to availability	10 minutes walk
Premier Inn	Waters Reach Trafford Park Manchester M17 1WS	0870 423 6450	£62 Room only	10 minutes walk
Ramada Hotel, Salford Quays 4*	17 Trafford Road Salford Quays M5 3AW	0161 870 7070	£74 RO / £84 BB single occupancy	10 minutes walk
Old Trafford Lodge	Lancs County Cricket Club Old Trafford Manchester M16 0PX	0161 874 3333	£64 Standard £69 Executive Includes Continental Breakfast	5 minutes drive
Holiday Inn Manchester West	Liverpool Street, Salford Manchester M5 4LT	0161 743 0080	From £69.00 Room Only, £79.00 BB	5 minutes drive
Radisson Edwardian Hotel 5*	Peter Street Manchester M5 2GP	0161 835 9929	From £130 BB	10 minutes drive
Yang Sing	36 Princess Street Manchester M1 4JY	0161 880 0188	From £149 BB (numbers dependent)	10 minute drive

FUTURE MEETINGS – 2011

8th - 10th September
20th – 21st October

ASSH Meeting, Las Vegas (BSSH will be the official Guest Nation)
Autumn Scientific Meeting, One Great George Street, London

CONTINUING MEDICAL EDUCATION

The following number of points have been awarded for each day:-
Thursday: 6.5 Friday: 6.0 Total: 12.5

TRADE EXHIBITORS**ACUMED**

Huebner House, The Fairground, Weyhill, Hampshire SP11 0QN
Telephone: 01264 774 450, Fax: 01264 774 477, Email: bob@acumed.uk.com
Contact: Mr R Craddock

STAND NO 3**ADVANTECH SURGICAL LTD**

Southgate Chambers, 37-39 Southgate Street, Winchester, Hampshire SO23 9EH
Telephone: 08451 305 866, Fax: 08451 305 866, Email: mail@advantechsurgical.com
Contact: Mr B Sharples

STAND NO 4**ALBERT WAESCHLE LTD**

11 Balena Close, Creekmoor, Poole, Dorset BH17 7DB
Telephone: 01202 601 177, Fax: 01202 650 022, Email: roger@albertwaeschle.com
Contact: Mr R Wood

STAND NO 5**ARTHREX LTD**

Unit 5, 3 Smithy Wood Drive, Smithy Wood Business Park, Sheffield S35 1QN
Telephone: 0114 232 9180, Fax: 0114 257 8929, Email: Emily.wilson@arthrex.co.uk
Contact: Ms E Wilson

STAND NO 6**BLACKWELL EXHIBITIONS**

183 Euston Road, London NW1 2BE
Telephone: 020 7611 2160, Fax: 020 7611 2163, Email: exhibitions@blackwell.co.uk
Contact: Mr R Demery-Kane

STAND NO 15**EVIDENT**

57 Wellington Court, Wellington Road, London NW8 9TD
Telephone: 020 7722 0072, Fax: 020 7722 0976, Email: hmc@evident.co.uk
Contact: Ms H McCutcheon

STAND NO 7**Evident**

...it's all about quality

Evident, the market leader in Loupes has 18 years unrivalled experience in providing and dispensing magnification. With a sales team that includes qualified Opticians, Surgeons can be reassured of receiving the best service.

Visit our stand to see the ultra-high quality, ExamVision range available in 2.3x, 2.8x, 3.5x, 4.2x & 5.0x – all with short barrels. Featuring the unique improved Galilean magnifying-system with dual achromatic German lenses – for a perfect image. Coupled with ultra-lightweight metal ocular casings, a contemporary range of ergonomic titanium frames including the NEW wrap around SPORTS frame and special protection shields; half or full face. Complement your loupes with one of the ExamVision portable light systems; latest LED technology, lightweight, up to 12 hours working time and charging in 2.5 hours.

.....it's all about quality

E: sales@evident.co.uk, W: www.evident.co.uk, **FreeCall 0500 321111**

MEDARTIS LTD

Suite 63, Annexe 4, Batley Business Park, Technology Drive, Batley, West Yorkshire WF17 6ER
Telephone: 01924 476 699, Fax: 01924 472 000, Email: nadia.gershkovick@medartis.com
Contact: Mrs N Gershkovich

STAND NO 1**NORTHSTAR ORTHOPAEDICS LTD**

26 Kingfisher Court, Hambridge Road, Newbury, Berkshire RG14 5SJ
Telephone: 01635 275380, Fax: 01635 275381, Email: julie@northstar-ortho.co.uk
Contact: Mr R Forster

STAND NO 8

TRADE EXHIBITORS continued

OSTEOTEC LTD

9 Silver Business Park, Airfield Way, Christchurch BH23 3TA
Telephone: 01202 87 885, Fax: 01202 487 886, Email: susann@osteotec.co.uk
Contact: Ms S Idres

STAND NO 2

PFIZER

Dorking Road, Walton on the Hill KT20 7NS
Telephone: 01737 330 564, Email: stephen.robinson12@pfizer.com
Contact: Mr S Robinson

STAND NO 13

SAGE PUBLICATIONS LTD

1 Oliver's Yard, 55 City Road, London EC1Y 1SP
Telephone: 020 7324 8517, Fax: 020 7324 8600, Email: Vicki.ellison@sagepub.co.uk
Contact: Ms V Ellison

STAND NO 14



SAGE is a leading international publisher of journals, books, and electronic media for academic, educational, and professional markets. Since 1965, SAGE has helped inform and educate a global community of scholars, practitioners, researchers, and students spanning a wide range of subject areas including business, humanities, social sciences, and science, technology and medicine. An independent company, SAGE has principal offices in Los Angeles, London, New Delhi, Singapore and Washington DC. www.sagepub.co.uk

SINCLAIR PHARMACEUTICAL LTD

Dane Mill Business Centre, Broadhurst Lane, Congleton, Cheshire CW12 1LA
Telephone: 01477 549 392, Fax: 08451 274 523, Email: acameron@sinclairpharma.com
Contact: Ms A Cameron

STAND NO 9

STRYKER TRAUMA

Stryker House, Hambridge Road, Newbury, Berkshire RG14 5EG
Telephone: 07917 065 400, Email: Jason.gwilt@stryker.com
Contact: Mr J Gwilt

STAND NO 12

TRB CHEMEDICA (UK) LTD

Med IC3, Keele University Science Park, Keele, Staffs ST5 5NP
Telephone: 0845 330 7556, Fax: 0845 330 7557, Email: dorothea@trbchemedica.co.uk
Contact: Ms D Alessi

STAND NO 10

VERTEC SCIENTIFIC

Unit 44, Easter Park, Benyon Road, Silchester, Reading RG7 2PQ
Telephone: 01189 702 104, Fax: 01189 701 861, Email: nviccars@vertec.co.uk
Contact: Mr K Lakin

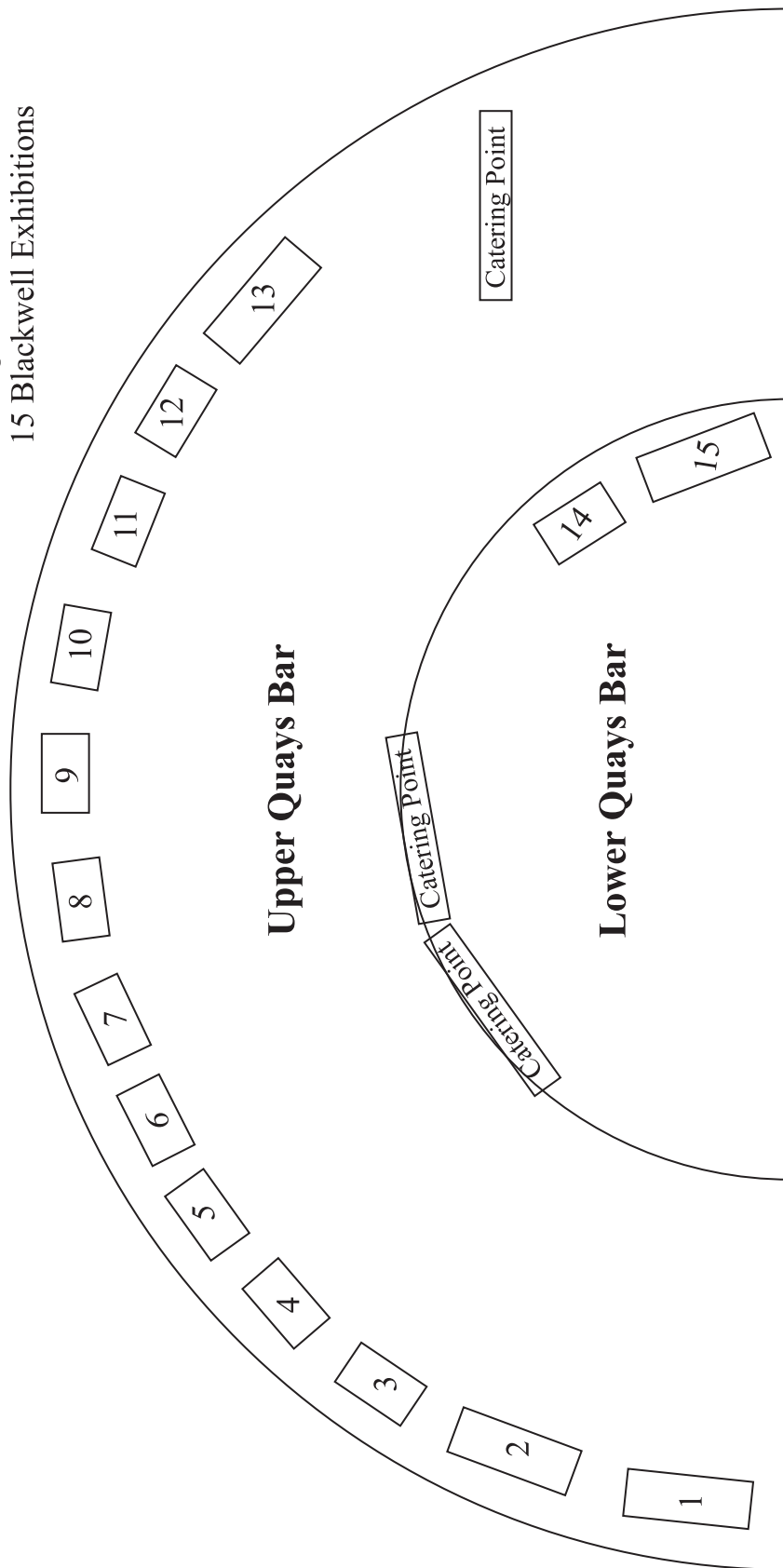
STAND NO 11

VENUE FLOOR PLAN

Quays Theatre Bar

- 8 Northstar Orthopaedic Ltd
- 9 Sinclair Pharmaceutical Ltd
- 10 TRB Chemedica (UK) Ltd
- 11 Vertec Scientific
- 12 Stryker Trauma
- 13 Pfizer
- 14 Sage Publications
- 15 Blackwell Exhibitions

- 1 Medartis
- 2 Osteotec
- 3 Acumed
- 4 Advantech Surgical Ltd
- 5 Albert Waeschle Ltd
- 6 Arthrex Ltd
- 7 Evident



Stand No 1, 2, 13, 14 and 15 = 3m x 1m

Stand No 3, 4, 5, 6, 7, 8, 9, 10, 11 and 12 = 2m x 1m

NOTES



BRITISH SOCIETY FOR SURGERY OF THE HAND

at The Royal College of Surgeons of England
35-43 Lincoln's Inn Fields, London WC2A 3PE
Telephone: 020 7831 5161, Fax: 020 7831 4041
E-mail: secretariat@bssh.ac.uk, Website: www.bssh.ac.uk

SPRING SCIENTIFIC MEETING

31 MARCH/1APRIL 2011

You have gained CME/CPD credits for attending this event. Please complete this questionnaire so that we learn how to improve future events. Thank you.

RATING SYSTEM: strongly agree 5...4...3...2...1 strongly disagree

	5	4	3	2	1
There was enough information available in advance	<input type="checkbox"/>	<input type="checkbox"/>	<input type="checkbox"/>	<input type="checkbox"/>	<input type="checkbox"/>
The venue was satisfactory	<input type="checkbox"/>	<input type="checkbox"/>	<input type="checkbox"/>	<input type="checkbox"/>	<input type="checkbox"/>
The quality of catering was satisfactory	<input type="checkbox"/>	<input type="checkbox"/>	<input type="checkbox"/>	<input type="checkbox"/>	<input type="checkbox"/>
The structure of the meeting was satisfactory	<input type="checkbox"/>	<input type="checkbox"/>	<input type="checkbox"/>	<input type="checkbox"/>	<input type="checkbox"/>
The level at which the meeting was pitched was correct	<input type="checkbox"/>	<input type="checkbox"/>	<input type="checkbox"/>	<input type="checkbox"/>	<input type="checkbox"/>
There was no overlapping	<input type="checkbox"/>	<input type="checkbox"/>	<input type="checkbox"/>	<input type="checkbox"/>	<input type="checkbox"/>
There was sufficient time for discussion	<input type="checkbox"/>	<input type="checkbox"/>	<input type="checkbox"/>	<input type="checkbox"/>	<input type="checkbox"/>
The standard of presentations was satisfactory	<input type="checkbox"/>	<input type="checkbox"/>	<input type="checkbox"/>	<input type="checkbox"/>	<input type="checkbox"/>
I found the poster presentations of interest	<input type="checkbox"/>	<input type="checkbox"/>	<input type="checkbox"/>	<input type="checkbox"/>	<input type="checkbox"/>
The abstracts were helpful	<input type="checkbox"/>	<input type="checkbox"/>	<input type="checkbox"/>	<input type="checkbox"/>	<input type="checkbox"/>
There was sufficient time to visit the trade exhibition stands	<input type="checkbox"/>	<input type="checkbox"/>	<input type="checkbox"/>	<input type="checkbox"/>	<input type="checkbox"/>
The trade exhibition was of interest to me	<input type="checkbox"/>	<input type="checkbox"/>	<input type="checkbox"/>	<input type="checkbox"/>	<input type="checkbox"/>
I found something new at the exhibition	<input type="checkbox"/>	<input type="checkbox"/>	<input type="checkbox"/>	<input type="checkbox"/>	<input type="checkbox"/>
There were adequate opportunities to meet other participants	<input type="checkbox"/>	<input type="checkbox"/>	<input type="checkbox"/>	<input type="checkbox"/>	<input type="checkbox"/>
I would attend a meeting such as this again	<input type="checkbox"/>	<input type="checkbox"/>	<input type="checkbox"/>	<input type="checkbox"/>	<input type="checkbox"/>

My hospital is refunding my registration fee Yes / No

PTO/.....

Suggestions of Content and Format of Future Meetings

General Comments

Thank you for taking the time to complete this form.

at The Royal College of Surgeons 35-43 Lincoln's Inn Fields London WC2A 3PE
Telephone: 020 7831 5162 Fax: 020 7831 4041
Email: secretariat@bssh.ac.uk Web: <http://www.bssh.ac.uk>