

## BSSH Evidence for Surgical Treatment 1

**Trigger Finger (Thumb)**

This guide on Trigger Finger (including trigger Thumb and Paediatric trigger) is based on evidence and current research and is intended to inform and guide tertiary referral.

<a href="#">Definition and Pathology</a> .....	1
<a href="#">Epidemiology and Clinical</a> .....	1
<a href="#">Evaluation</a> .....	2
<a href="#">Conservative treatment</a> .....	2
<a href="#">Paediatric Trigger</a> .....	3
<a href="#">Surgery</a> .....	3
<a href="#">British Society for Surgery of the Hand recommendations for Treatment</a> .....	4
<a href="#">Treatments without evidence:</a> .....	4
<a href="#">Treatment plan: diagram</a> .....	5
<a href="#">References</a> .....	6
<a href="#">Detailed References</a> .....	7

**Definition / Pathology**

Trigger finger (TF), or Stenosing Tenosynovitis, is an acquired condition in which the sheath for the flexor tendon of a finger or the thumb thickens and narrows such that the flexor tendon cannot glide freely through it. This may cause pain, intermittent snapping (“triggering”) or actual locking (in flexion or extension) of the affected digit. These symptoms are commonly worse first thing in the morning.

The pathological change in the flexor sheath is fibrocartilaginous metaplasia and hypertrophy of its “A1” pulley ([Sampson, 1991](#)). This causes a tender nodule at the base of the finger in the palm.

**Epidemiology/ Clinical**

The overall lifetime incidence of trigger digit is 2% ([Moore, 2000](#)). It commonly affects the thumbs, but not the fingers, of young children causing a flexion deformity of the interphalangeal joint. It also occurs throughout adulthood, most frequently occurs in the 5<sup>th</sup>-6<sup>th</sup> decades ([Wolfe, 2005](#)), and is then more common in woman. Diabetes and thyroid disease are risk factors for trigger digit, and it may occur in association with rheumatoid arthritis, kidney disease and other rarer disorders.

Triggering may affect single digits, including the thumb, or multiple digits and the diagnosis is clinical and based on a history of locking or stiffness of the affected digit(s), tenderness in the palm of the hand at the base of the affected finger and palpable clicking or locking of the affected digit during active movement. Differential diagnoses include Dupuytren’s contracture, post-traumatic joint contracture or locking of the metacarpophalangeal joint (rare). Spontaneous recovery may occur in up to 29% of patients ([Moore, 2000](#)). There is no clear association with occupation ([Trezies 1998](#)).

[Go to the top](#)

## Severity of Trigger Finger ( adapted from [Wolfe](#) 2005, Green's operative hand surgery)

- **Mild** (“pre-triggering”)
  - History of
    - pain
    - catching or “click”
  - Tender A1 pulley; but fully mobile finger
- **Moderate**
  - Triggering with:
    - A - Difficulty actively extending finger
    - B - Need for passive finger extension  
Loss of complete active flexion
- **Severe**
  - Fixed contracture

### Trigger Digit in Adults

**Consevative treatment.** Spontaneous recovery may occur with time. In one series 83% resolved spontaneously, but only after an average of 7 months ([Schofield](#), 1993).

**Steroid Injection** is an effective therapy for trigger finger and thumb. Success rates for a single injection of either soluble or insoluble steroid ([Ring](#) 2008 with commentary by: [Chung](#) 2008), placed either within, or over, the flexor sheath vary between 49-78% ([Lambert](#) 1992, [Murphy](#) 1995, [Akhtar](#) 2007, [Fleisch](#) 2007, [Peters-Veluthamaningal](#) 2008).

- A second injection is often (50%) successful if the first has no, or only temporary, effect ([Akhtar](#) 2007, [Ring](#), 2008). Triamcinolone may have a more rapid effect than Dexamethasone ([Ring](#), 2008). Steroid injections have few complications ([Baumgarten](#) 2008, [Peters-Veluthamaningal](#) 2008) and are safely given in the primary care setting ([Akhtar](#) 2005, [Peters-Veluthamaningal](#) 2008).
- The response rates to steroid injection in patients with diabetes, rheumatoid arthritis is lower than in those with no risk factors for trigger digit ([Akhtar](#) 2005, [Akhtar](#) 2007, [Baumgarten](#) 2007, [Baumgarten](#) 2008). However up to 60% of *diabetic* patients are successfully treated with steroid injections, though the success rate is lower if multiple digits are involved. There is no evidence that simple sheath dilatation with saline or lignocaine offers any therapeutic benefit ([Lambert](#) 1992, [Murphy](#) 1995, [Baumgarten](#) 2007).

**Splinting** is an alternative therapy for those unwilling to contemplate steroid injection or surgery. There is some evidence that this may be effective in adult ([Patel](#) 1992) and paediatric populations ([Bae](#) 2008, [Ogino](#) 2008). There is no evidence to suggest that work-place modification (ergonomic adjustments) or physiotherapy help in the management of work-related trigger finger.

[Go to the top](#)

**Surgery** (trigger finger release) is indicated:

- after failed conservative treatment
- for recurrent triggering after 1-2 injections of steroid
- if there are severe symptoms at presentation
- in people populations who are unlikely to benefit from steroid injections (for example a diabetic with many digits affected and severe symptoms)

**Surgical division** of the A1 annular pulley of the flexor sheath of the digit, either by conventional open, or percutaneous, release is an effective treatment with a high success rate, low complication rate and short recovery period (3-4 weeks). It is usually done on a daycase basis under local anaesthetic and provides a permanent “cure” when performed by appropriately trained surgeons.

[Go to the top](#)

### **Paediatric Trigger Thumb**

This is an acquired condition <sup>(Bac 2008, Ogino 2008)</sup> which usually presents between the ages of 6 months and 2 years. Typically the thumb interphalangeal joint is locked in flexion and cannot be actively or passively extended, and there is a palpable A1 pulley (“Notta” node) on the palmar aspect of the metacarpophalangeal joint. Treatment is not mandatory for mild cases with only slight flexion deformity. Treatment with steroid injection has not been reported and is not practiced.

- Observational and retrospective studies suggest that paediatric trigger thumbs spontaneously resolve in between 36-78% of patients by skeletal maturity. This recovery may be assisted by splinting and passive stretching programmes.
- Surgical release of the A1 pulley of the flexor sheath of the thumb is almost always successful <sup>(Bac 2008, Ogino 2008)</sup> and is typically performed as a day-case under a short general anaesthetic. There is no ideal age for surgery, the timing of which is determined by the severity of the flexion deformity, the duration of the problem and the parents attitude to a “wait and see” policy in the hope of spontaneous resolution. However surgery is typically performed by the age of 3 years <sup>(Dinham 1974)</sup> although other authors suggest waiting to the age of 5 <sup>(Ogino 2008)</sup>.

## **British Society for Surgery of the Hand recommendations for Treatment of Trigger Digit in Adults**

- **Mild**
  - Analgesia
- **Moderate**
  - Steroid injection to flexor sheath
- **Severe or failed non-operative treatment**
  - Surgical trigger release

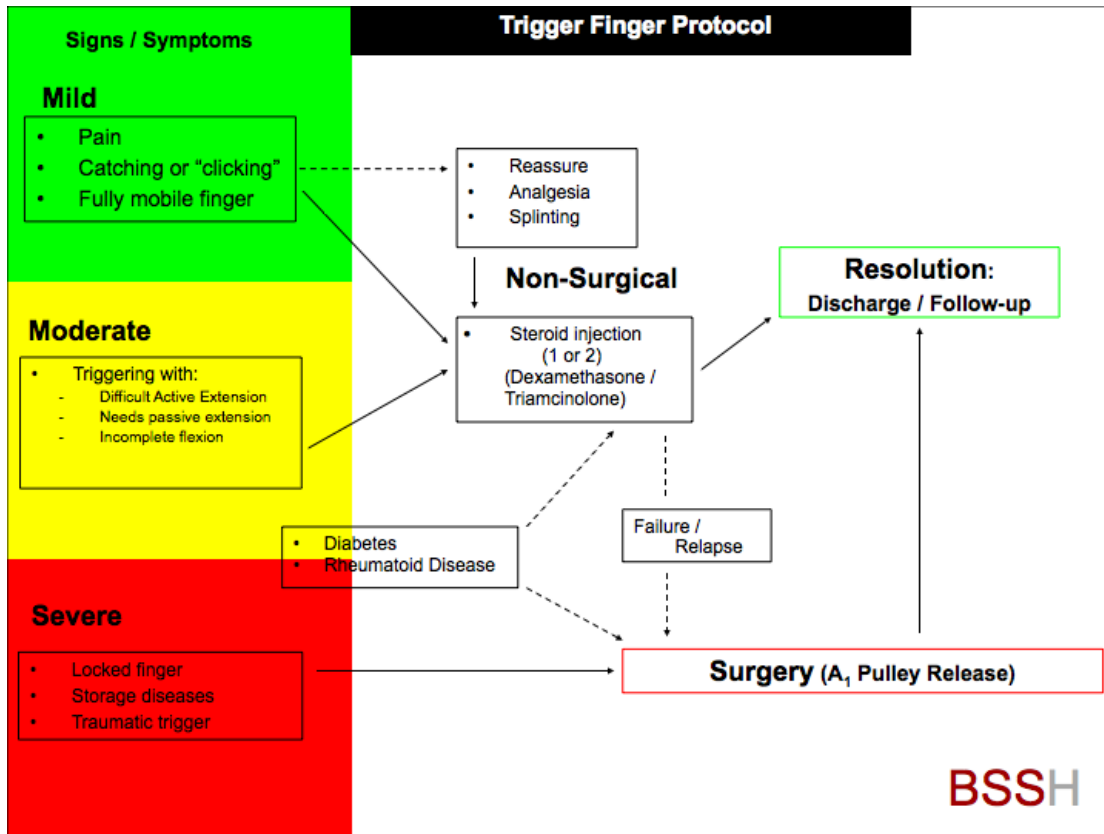
### **Treatments without evidence:**

No effect is demonstrated for the following treatments which are **Not Recommended:**

- NSAID's, except for simple analgesia
- Placebo injection (Lambert 1992, [Murphy 1995](#), [Baumgarten 2007](#))
- Work-place modifications ([Trezies 1998](#))

[Go to the top](#)

**Treatment plan: diagram**



[Go to the top](#)

## **Research Opportunities**

- Proper community-based study of untreated trigger thumb in children

## **References**

[Wolfe SW](#). Tenosynovitis, 2137-2158, Chapter 60. Green's Operative Hand Surgery Ed's Green DP, Hotchkiss RN, Pederson WC, Wolfe SW . Elsevier, Churchill Livingstone, 2005.

[Sampson SP](#), [Badalamente MA](#), [Hurst LC](#), [Seidman J](#). Pathobiology of the human A1 pulley in trigger finger. J Hand Surg [Am]. 1991 Jul;16(4):714-21.

[Ryzewicz M](#), [Wolf JM](#). Trigger digits: principles, management, and complications. J Hand Surg [Am]. 2006 Jan;31(1):135-46. Review.

[Moore JS](#). Flexor tendon entrapment of the digits (trigger finger and trigger thumb). J Occup Environ Med. 2000 May;42(5):526-45. Review.

[Trezies AJ](#), [Lyons AR](#), [Fielding K](#), [Davis TR](#). Is occupation an aetiological factor in the development of trigger finger? J Hand Surg [Br]. 1998 Aug;23(4):539-40.

[Schofield CB](#), [Citron ND](#). The natural history of adult trigger thumb. J Hand Surg [Br]. 1993 Apr;18(2):247-8.

[Ring D](#), [Lozano-Calderón S](#), [Shin R](#), [Bastian P](#), [Mudgal C](#), [Jupiter J](#). A prospective randomized controlled trial of injection of dexamethasone versus triamcinolone for idiopathic trigger finger. J Hand Surg [Am]. 2008 Apr;33(4):516-22; discussion 523-4.

[Murphy D](#), [Failla JM](#), [Koniuch MP](#). Steroid versus placebo injection for trigger finger. J Hand Surg [Am]. 1995 Jul;20(4):628-31. Erratum in: J Hand Surg [Am] 1995 Nov;20(6):1075. **Comment in:** J Hand Surg [Am]. 1996 May;21(3):530.

[Lambert MA](#), [Morton RJ](#), [Sloan JP](#). Controlled study of the use of local steroid injection in the treatment of trigger finger and thumb. J Hand Surg [Br]. 1992 Feb;17(1):69-70.

[Akhtar S](#), [Burke FD](#). Study to outline the efficacy and illustrate techniques for steroid injection for trigger finger and thumb. Postgrad Med J. 2006 Nov;82(973):763-6. Review.

[Akhtar S](#), [Bradley MJ](#), [Quinton DN](#), [Burke FD](#). Management and referral for trigger finger/thumb. BMJ. 2005 Jul 2;331(7507):30-3.

[Fleisch SB](#), [Spindler KP](#), [Lee DH](#). Corticosteroid injections in the treatment of trigger finger: a level I and II systematic review. J Am Acad Orthop Surg. 2007 Mar;15(3):166-71. Review.

:

[Peters-Veluthamaningal C](#), [Winters JC](#), [Groenier KH](#), [Jong BM](#). Corticosteroid injections effective for trigger finger in adults in general practice: a double-blinded randomised placebo controlled trial. *Ann Rheum Dis*. 2008 Sep;67(9):1262-6. Epub 2008 Jan 7.

[Baumgarten KM](#). Current treatment of trigger digits in patients with diabetes mellitus. *J Hand Surg [Am]*. 2008 Jul-Aug;33(6):980-1. Review.

[Baumgarten KM](#), [Gerlach D](#), [Boyer MI](#). Corticosteroid injection in diabetic patients with trigger finger. A prospective, randomized, controlled double-blinded study. *J Bone Joint Surg Am*. 2007 Dec;89(12):2604-11.

[Taras JS](#), [Raphael JS](#), [Pan WT](#), [Movagharnia F](#), [Sotereanos DG](#). Corticosteroid injections for trigger digits: is intrasheath injection necessary? *J Hand Surg [Am]*. 1998 Jul;23(4):717-22.

[Patel MR](#), [Bassini L](#). Trigger fingers and thumb: when to splint, inject, or operate. *J Hand Surg [Am]*. 1992 Jan;17(1):110-3.

[Bae DS](#). Pediatric trigger thumb. *J Hand Surg [Am]*. 2008 Sep;33(7):1189-91.

[Ogino T](#). Trigger thumb in children: current recommendations for treatment. *J Hand Surg [Am]*. 2008 Jul-Aug;33(6):982-4. Review.

[Dinham JM](#), [Meggitt BF](#). Trigger thumbs in children. A review of the natural history and indications for treatment in 105 patients. *J Bone Joint Surg Br*. 1974 Feb;56(1):153-5.

