

BSSH Evidence for Surgical Treatment 1

Wrist Ganglion

This guide on Wrist Ganglia is based on evidence and current research and is intended to inform and guide tertiary referral.

Definition	1
Prevalence and Incidence	1
Natural History	1
Clinical	2
Classification	2
Conservative treatment	2
Surgery and Outcomes	3
British Society for Surgery of the Hand recommendations for Treatment	4
Treatments without evidence:	4
Treatment plan: diagram	5
References	6
Detailed References	7

Definition and Pathology

Ganglia are the commonest soft tissue tumours of the hand and wrist. Wrist ganglia may be found either on the dorsal or palmar - commonly radial - aspects of the wrist.

Dorsally they usually arise singly and originate from the scapho-lunate joint. On the volar wrist surface, they usually arise from the radio-carpal or scapho-trapezial joints.

Ganglia have been reported to occur in almost every joint in the hand and wrist ([Athanasian 2005](#)).

Two other common clinical entities are flexor sheath ganglia and “mucous” cysts associated with the distal inter-phalangeal joint.

Histologically they are composed of a thin connective tissue capsule made up of compressed collagen fibres lined with flattened cells. There is no evidence of a synovial or epithelial lining. Cyst contents consist of a hyaluronic acid-rich mucin-filled uni- or multi-loculated cystic cavities with glucosamine, globulin and albumin ([Athanasian 2005](#)). Malignant degeneration has never been reported.

Prevalence and Incidence

Population prevalence is unknown as many people live comfortably with their ganglia with no recourse to medical referral. Historical evidence would suggest incidences of between 25-43/ 100 000 population ([Janzon 1981](#)). In one study MRI scans were performed on 103 healthy asymptomatic volunteers and wrist ganglia were found in 53 ([Lowden 2005](#)). Ganglia are more prevalent in females ([Barnes 1964](#)) and occur most commonly in the second to fourth decades of life ([Minotti 2002](#)). They are also common in the paediatric and elderly population although in children the majority resolve in less than 1 year ([Calif 2005](#), [Coffey 2008](#)). Ganglia are the second commonest cause for referral to hand units with one UK centre showing a rise from 43.9 per 100000 per year in 1989/90 to 55 per 100000 per year in 2000 ([Burke 2003](#)).

Natural History

The aetiology of common wrist ganglia remains unknown. Onset may be sudden or insidious. However, specific traumatic events precede 10% of cases and repeated minor trauma may be

a factor in their development ([Angelides 1976](#)). There is no correlation with occupation and they may subside with rest and enlarge with activity and rupture or disappear spontaneously ([Athanasian 2005](#)).

Clinical

Clinical presentation is usually with a lump and often pain. The “lump” raises cosmetic and cancer concerns. Westbrook et al. studied the views of 50 patients attending a hand clinic with a diagnosis of ganglion and found that 38% of patients present with cosmetic concerns only, 28% concerned that it was cancer, 26% with pain and only 8% with restricted hand function or altered sensation ([Westbrook 2000](#)).

Examination of the lump will usually confirm the clinical suspicion of a ganglion. Trans-illumination of a lump in the usual anatomical location will confirm a fluid filled cyst unless this cyst is very small or deep ([Burke 2003](#)).

Ultrasound scan is an effective way of demonstrating ganglia which may be either deep-seated or too small to palpate ([Osterwalder 1997](#)). MRI scanning is of use in diagnosis and one study suggests that MRI is a sensitive and relatively specific imaging modality for the occult ganglion but was restricted by a sample size of 20 ([Goldsmith 2008](#)).

Important differential diagnoses include:

- Extensor tenosynovitis in rheumatoid disease
- Dorsal wrist pain of unknown aetiology due to occult wrist ganglia.
- Radial artery aneurysm over volar wrist
- Malignant soft tissue tumour

Classification of Ganglia

- **Mild**
 - Asymptomatic lump
- **Moderate**
 - Symptomatic lump; long duration of symptoms
 - Occult ganglia
 - Cancer- phobia
- **Severe**
 - Severe pain with restriction of activities of daily living; concern re diagnosis

[Go to the top](#)

Conservative and “Non-operative” Treatment

Reassurance

- A 6 year prospective study showed that 33% of dorsal and 45% of volar ganglia will resolve spontaneously ([Dias 2007](#)). Furthermore an internal audit in Derby, with 10 year

follow up, showed these figures increase to 51% and 63% respectively ([Burke 2003](#)). Therefore, in asymptomatic ganglia, reassurance can be reasonably employed.

Aspiration with or without injection

- There is evidence that aspiration of a ganglion may alleviate symptoms for a varying amount of time ([Nield 1986](#), [Oni 1992](#)). There is however some reluctance to aspirate volar wrist ganglia because of the proximity of the radial artery and a theoretical risk of damage to it ([Burke 2007](#)). At present there is no evidence for this. Single aspiration yields a recurrence rate of 59-88% ([Nield 1986](#), [Burke 2003](#)). This can be improved by three serial aspirations to 12-15% ([Zubowicz 1987](#), [Oni 1992](#)). Aspiration has also been employed as a tool for reassurance in the 28% of patients who presented with concerns that their ganglion was a malignant lesion ([Westbrook 2000](#), [Stephen 1999](#)).
- There is no clear evidence to suggest that aspiration coupled with instillation of steroid affects recurrence rate ([Varley 1997](#)). There is some evidence that injection of a combination of steroid and hyaluronidase may reduce recurrence rates further ([Paul 1997](#)). However, the recurrence rate after a single aspiration and injection of hyaluronidase has been shown to be inferior to surgical excision ([Akkerhuis 2002](#)).
- In both aspiration alone and aspiration with injection, it has been shown that only 25% of patients whose ganglia subsequently recurred after the first treatment requested surgical excision due to the confirmation of the benign nature of the lesion ([Westbrook 2000](#)).

Operative Treatment

- Surgical excision of the cyst with capsule and any attachments to the underlying wrist ligaments may be performed either by open surgery or arthroscopically ([Kang 2008](#), [Rocchi 2008](#)).
- Published recurrence rates after excision vary dramatically from 1% - 40% ([Clay 1988](#), [Dias 2003 & 2007](#), [Angelides 2005](#)). Recurrence rate may depend on the surgical technique. Further investigation is needed to define what factors of the surgical technique are important in preventing recurrence.
- There is evidence that pre-operative pain persists, after excision, in up to 27% of patients ([Clay 1988](#)), even though this study reported only a 3% recurrence rate ([Clay 1988](#)).
- Two large studies looked independently at treatments for volar and dorsal wrist ganglia over 5 and 6 years respectively. No significant difference was identified between the groups that had received reassurance, aspiration or surgery. Patient satisfaction was higher in the group that received surgical intervention ([Dias 2003 & 2007](#)).
- Treatment for symptomatic ganglia therefore remains controversial.

British Society for Surgery of the Hand recommendations for Treatment

- **Mild**
 - Reassure / Observe

- **Moderate**
 - Reassure / Observe
 - Aspiration for cancer reassurance
 - Refer for ultrasound / MRI if concerns re diagnosis
- **Severe**
 - Refer for surgery

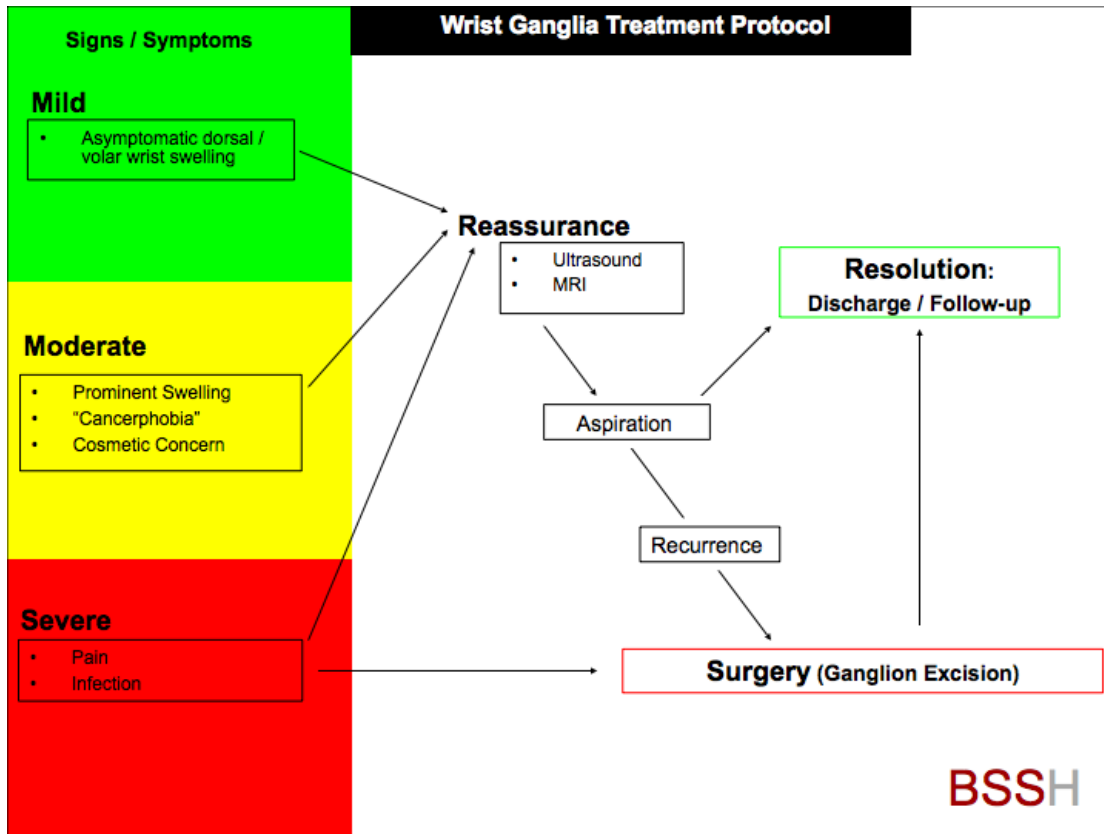
Treatments without evidence:

No effect is demonstrated for the following treatments which are Not Recommended:

- Aspiration with simultaneous injection of steroid ([Varley 1997](#))
- Aspiration and multiple wall puncture ([Richman.1987](#))

[Go to the top](#)

Treatment plan: diagram



[Go to the top](#)

Research Opportunities

- Prospective randomised controlled trials of aspiration vs aspiration plus hyaluronidase in symptomatic ganglia
- Prospective randomised controlled trials of excision vs aspiration in symptomatic ganglia

References

[M Jagers Op Akkerhuis, M Van Der Heijden, P R Brink](#). Hyaluronidase versus surgical excision of ganglia: a prospective, randomized clinical trial. *Journal of Hand Surgery (Br)*;2002 Jun;27(3) pp. 256-8.

[A C Angelides, P F Wallace](#). The dorsal ganglion of the wrist: its pathogenesis, gross and microscopic anatomy, and surgical treatment. *The Journal of hand surgery (Am)*. 1976 vol. 1 (3) pp. 228-35

[E A Athanasian](#). *Green's Operative Hand Surgery*. Ed: D P Green, R N Hotchkiss, W C Pederson, S W Wolfe. Fifth Edition 2005. pp. 2211 – 2265

[Janzon L, Niechajev IA](#). Wrist ganglia. Incidence and recurrence rate after operation. *Scand J Plast Reconstr Surg*. 1981;15(1):53-6.

[W E Barnes, R D Larson, J L Posch](#). Review of ganglia of the hand a wrist with analysis of surgical treatment. *Plastic and Reconstructive Surgery*. 1964 vol. 34 pp. 570-8

[F D Burke, M J Bradley](#). A proposal justifying an alternative referral practice from primary care for three common hand surgery diagnoses. *Postgraduate medical journal*. 2007 vol. 83 (984) pp. 616-7

[F D Burke, E Y Melikyan, M J Bradley, J J Dias](#). Primary care referral protocol for wrist ganglia. *Postgraduate medical journal*. 2003 vol. 79 (932) pp. 329-31

[E Calif, S Stahl, S Stahl](#). Simple wrist ganglia in children: a follow-up study. *Journal of Pediatric Orthopaedics*. 2005 Nov;14(6) pp. 448-50.

[N R Clay, D A Clement](#). The treatment of dorsal wrist ganglia by radical excision. *Journal of hand surgery (Br)*. 1988 vol. 13 (2) pp. 187-91.

[MJ Coffey, M Fazlur Rahman, SM Thirkannad](#). Pediatric Ganglion Cysts of the hand and wrist: an epidemiologic analysis. *Hand (NY)*. 2008 Dec;3(4) pp. 359-62.

[J Dias, K Buch](#). Palmar wrist ganglion: does intervention improve outcome? A prospective study of the natural history and patient-reported treatment outcomes. *Journal of Hand Surgery (Br)*; 2003 Apr;28(2) pp. 172-6.

[J J Dias, V Dhukaram, P Kumar](#). The natural history of untreated dorsal wrist ganglia and patient reported outcome 6 years after intervention. *The Journal of hand surgery (European volume)*. 2007 vol. 32 (5) pp. 502-8

[S Goldsmith, S S Yang](#). Magnetic resonance imaging in the diagnosis of occult dorsal wrist

ganglions. *Journal of Hand Surgery (European Volume)*;2008 Oct;33(5) pp. 595-9.

[L Kang, E Akelman, AP Weiss](#). Arthroscopic versus open dorsal ganglion excision: a prospective, randomized comparison of rates of recurrence and of residual pain. *Journal of Hand Surgery (Am)*; 2008 Apr;33(4) pp. 471-5

[C M Lowden, M Attiah, G Garvin, J C Macdermid, S Osman, K J Faber](#). The prevalence of wrist ganglia in an asymptomatic population: magnetic resonance evaluation. *Journal of hand surgery (Br)*. 2005 vol. 30 (3) pp. 302-6

[P Minotti, J S Taras](#). Ganglion cysts of the wrist. *Journal of American Society for Surgery of the Hand*. 2002 vol. 2 pp. 102-7

[D V Nield, D M Evans](#). Aspiration of ganglia. *Journal of hand surgery (Br)*. 1986 vol. 11 (2) pp. 264

[J A Oni](#). Treatment of ganglia by aspiration alone. *Journal of hand surgery (Br)*. 1992 vol. 17 (6) pp. 660

[J J Osterwalder, R Widrig, R Stober, A Gächter](#). Diagnostic validity of ultrasound in patients with persistent wrist pain and suspected occult ganglion. *The Journal of Hand Surgery (Am)*. 1997 vol. 22 (6) pp. 1034-40

[A S Paul, D H Sochart](#). Improving the results of ganglion aspiration by the use of hyaluronidase. *Journal of hand surgery (Br)*. 1997 vol. 22 (2) pp. 219-21

[J A Richman, R H Gelberman, W D Engber, P B Salamon, D J Bean](#). Ganglions of the wrist and digits: results of treatment by aspiration and cyst wall puncture. *The Journal of hand surgery (Am)*. 1987 vol. 12 (6) pp. 1041-3

[L Rocchi, A Canal, F Fanafi, F Catalano](#). Articular ganglia of the volar aspect of the wrist: arthroscopic resection compared with open excision. A prospective randomised study. *Scandinavian journal of plastic and reconstructive surgery and hand surgery*;2008;42(5) pp. 253-9

[A B Stephen, A R Lyons, T R Davis](#). A prospective study of two conservative treatments for ganglia of the wrist. *Journal of hand surgery (Br)*. 1999 vol. 24 (1) pp. 104-5

[G W Varley, M Needoff, T R Davis, N R Clay](#). Conservative management of wrist ganglia. Aspiration versus steroid infiltration. *Journal of hand surgery (Br)*. 1997 vol. 22 (5) pp. 636-7

[A P Westbrook, A B Stephen, J Oni, T R Davis](#). Ganglia: the patient's perception. *Journal of hand surgery (Br)*. 2000 vol. 25 (6) pp. 566-7

[V N Zubowicz, C H Ishii](#). Management of ganglion cysts of the hand by simple aspiration. *The Journal of hand surgery (Am)*. 1987 vol. 12 (4) pp. 618-20

